

### Practical example of using our

### Pocket Laser

Clinical case study by

Dr Marco Colombo



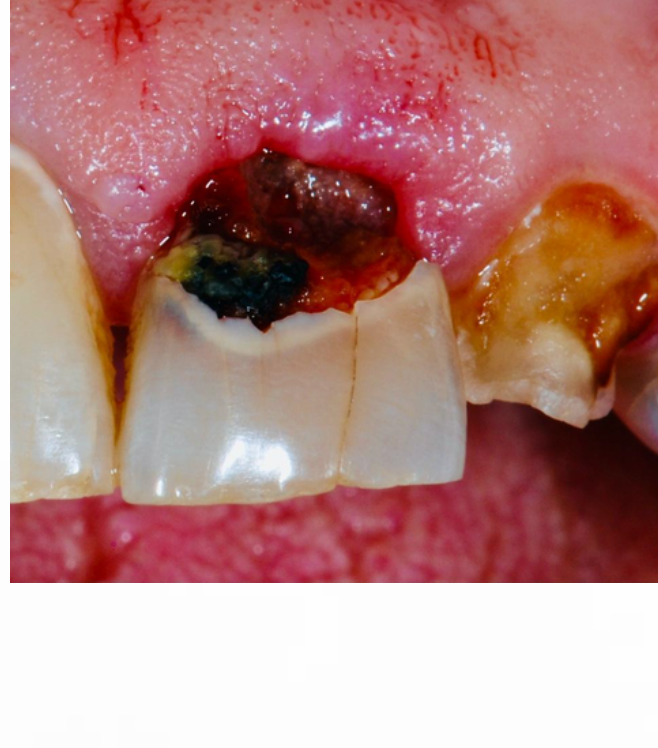- PhD in Experimental Surgery and Microsurgery
- RTDA at the University of Pavia Department of Clinical Diagnostic and Paediatric Surgical Sciences
- National ASN second band
- President of ANDI Pavia
- National Scientific Director of ANDI
- Adviser Scientific Committee FDI

- Clinical case using the **Pocket Laser** diode laser



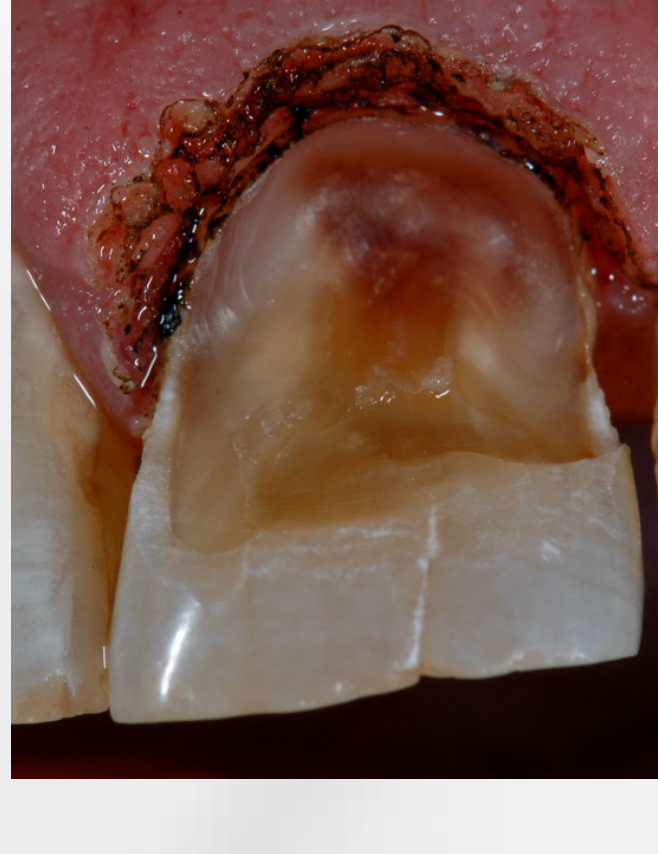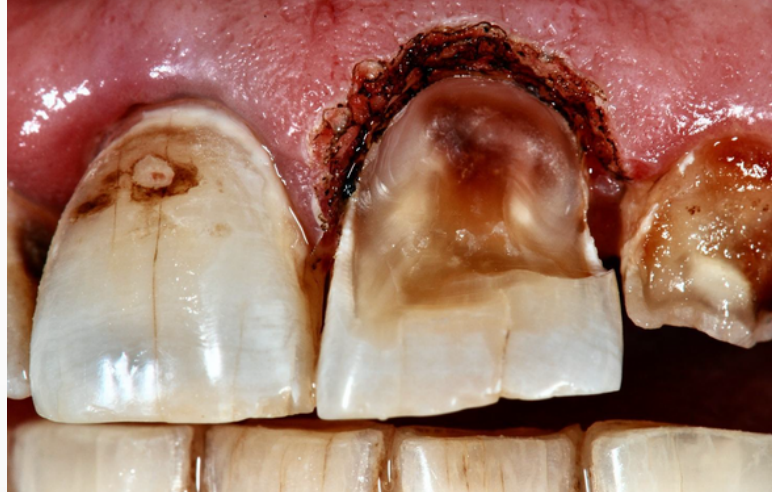The case presents a laser-assisted gingivectomy procedure to improve tooth contours for proper direct composite reconstruction.

The male patient has destructive caries on tooth element 21 and other diffuse carious pathologies on several elements.



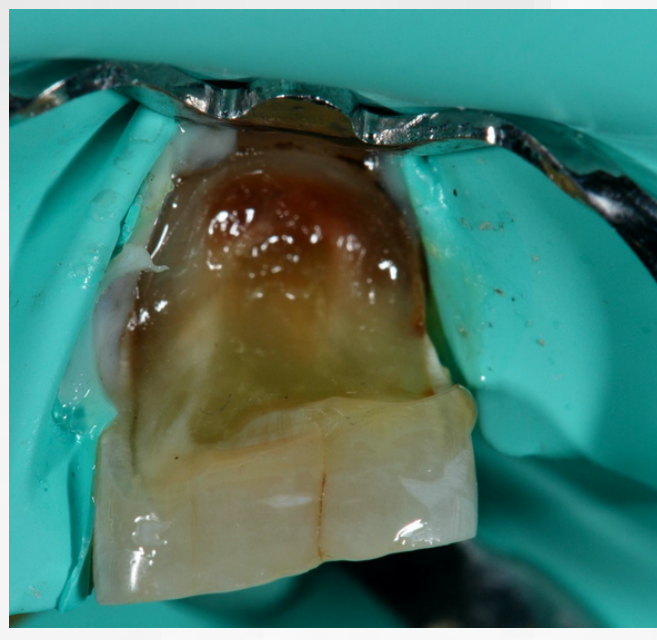
1

A diode laser operation is decided to remove part of the hypertrophied gingiva.



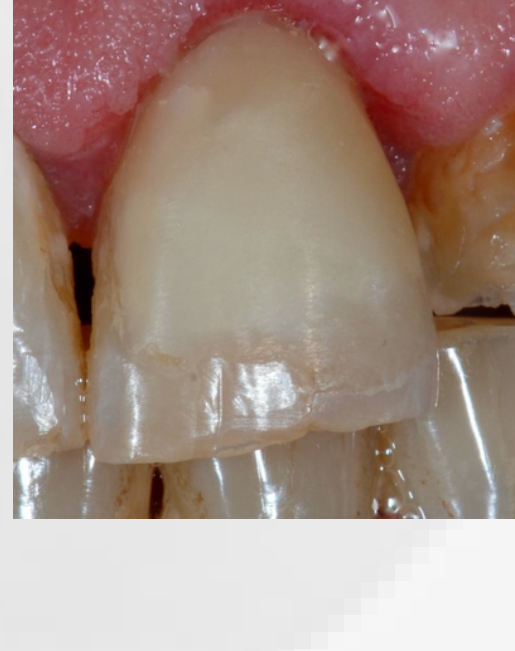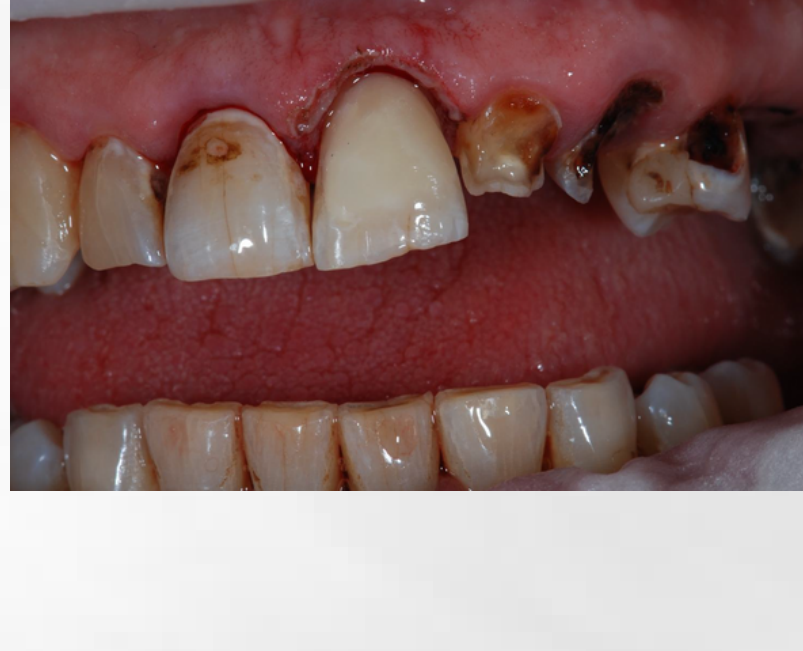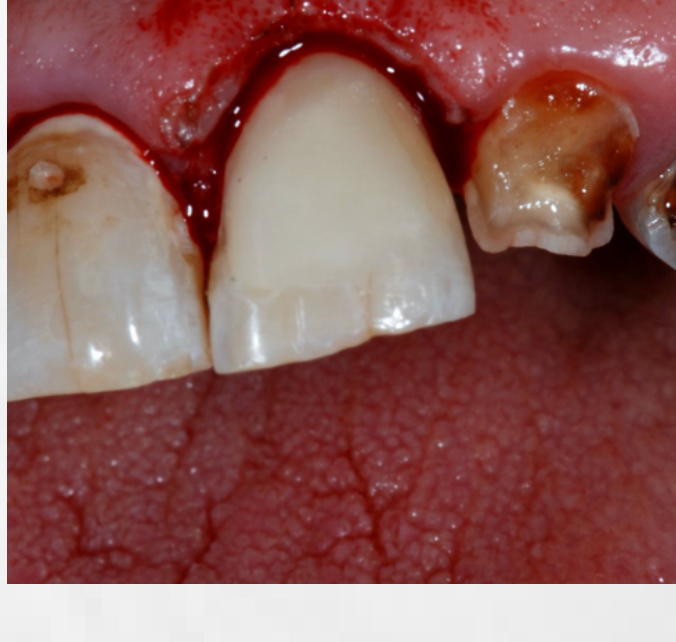2

Isolating the element with Dental dam



3

And reconstructed in composite material



## ABOUT US

**88Dent** is an Italian company engaged in the design, production and commercialisation of innovative solutions and high-quality technologies for dentistry.

88Dent's most important current challenge is to create a transition from analogue to digital workflow with scanners, milling machines, lasers, sintering furnaces, suction systems combined with modelling and design software, as well as ceramic and precious alloy consumables.

Visit our website to discover our products.

[www.88dent.com](http://www.88dent.com)

8853 Spa  
Via Pitagora, 11 | 20016 Pero (Mi)  
+39.02.8853.501 | [info@88dent.com](mailto:info@88dent.com)