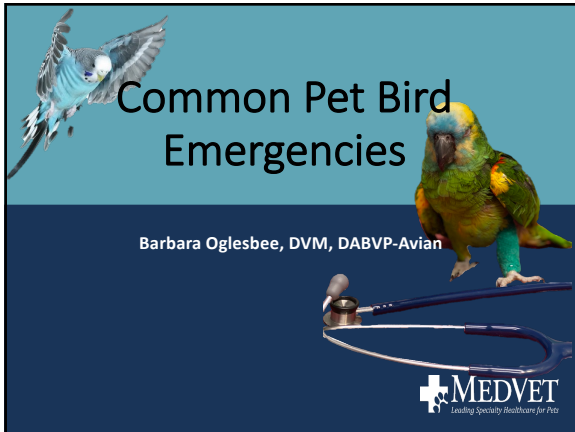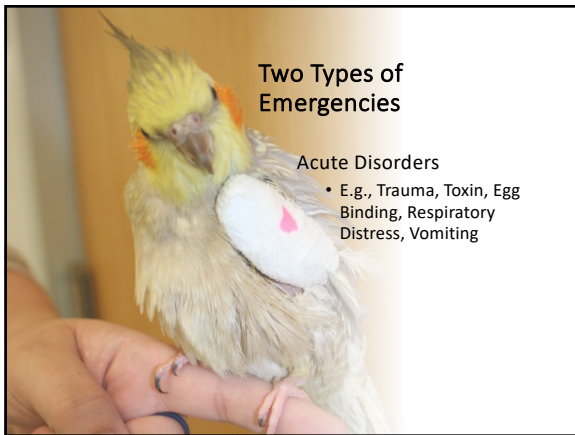

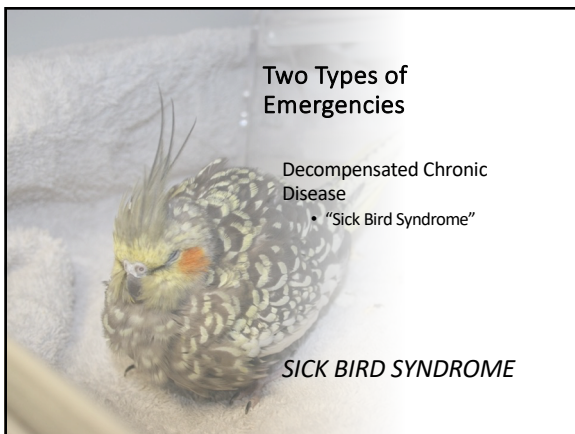
1



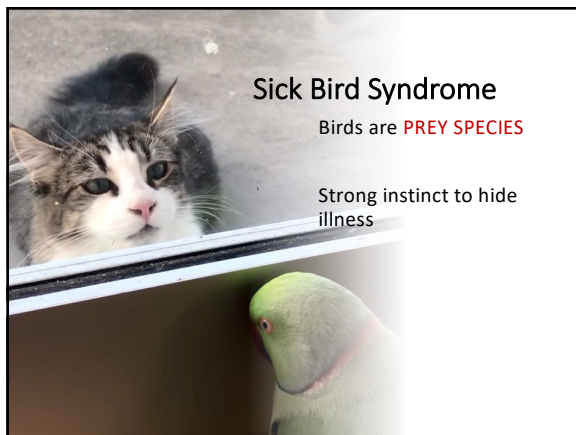
2



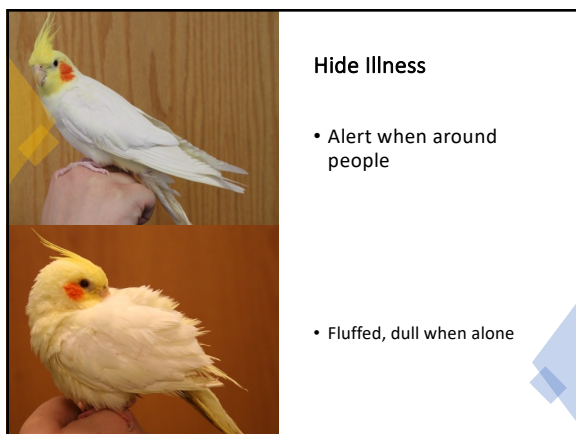3



4



5



6

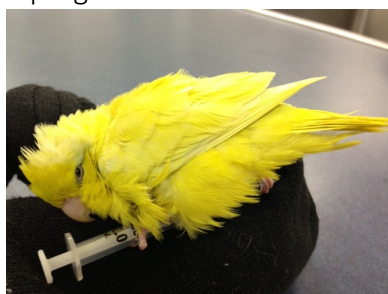If so sick, he cannot hide illness in busy, strange environment - guarded



MEDVET

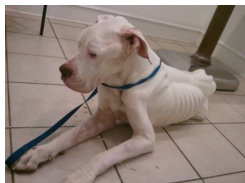
7

If so sick, he cannot even stand – Grave prognosis

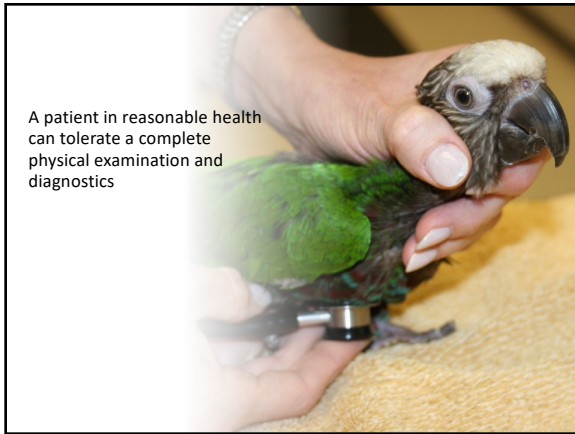

MEDVET

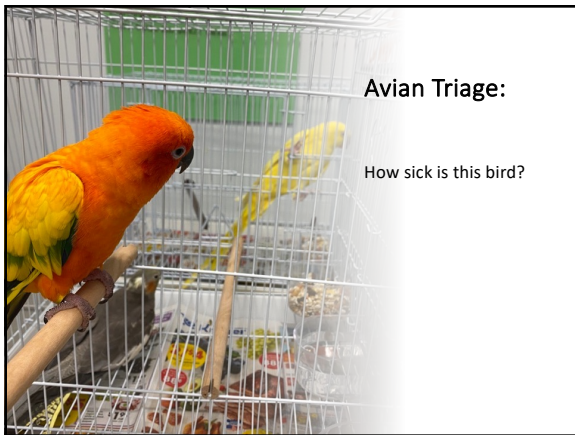8



9



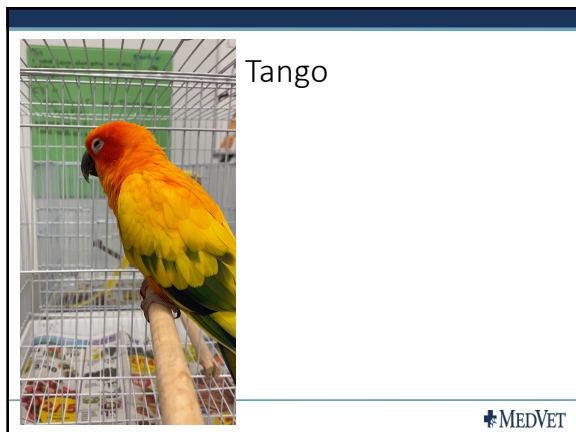10




11



12



13



14



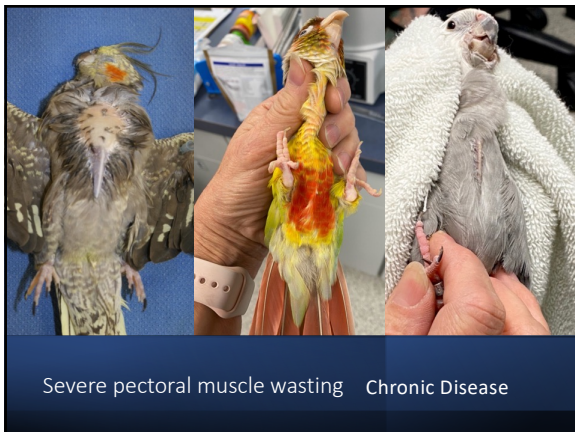15



16

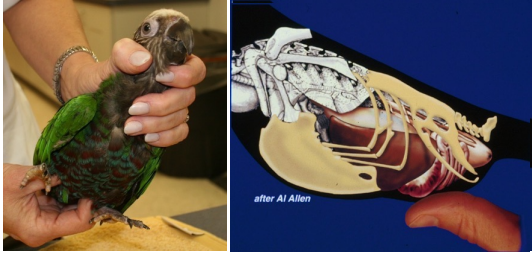


17



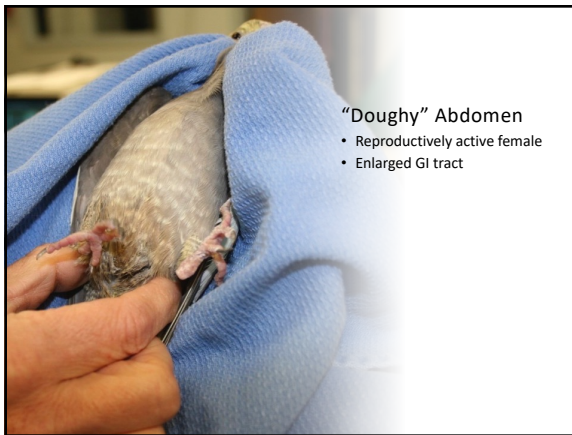18

Palpate Abdomen



MEDVET

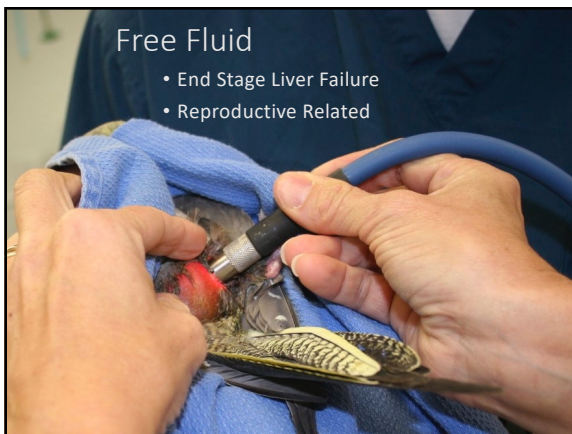
19



"Doughy" Abdomen

- Reproductively active female
- Enlarged GI tract


20



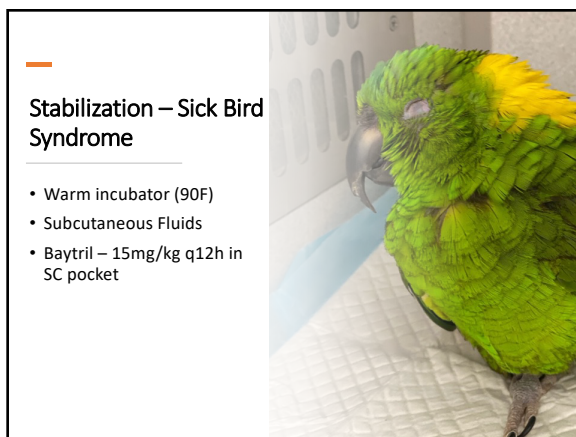
Free Fluid

- End Stage Liver Failure
- Reproductive Related

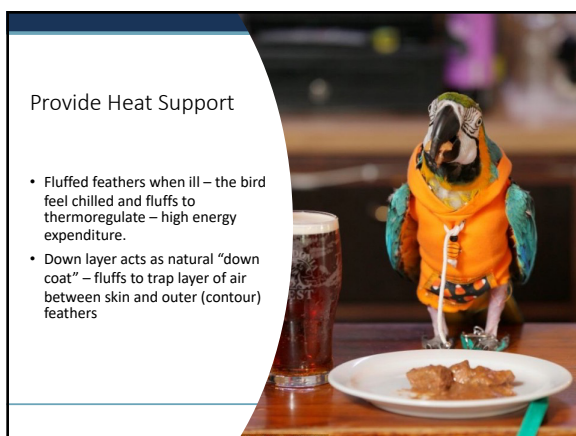21



22



23




24



Fluid Needs:

- Most sick birds – estimate as 5-10% dehydrated
- Maintenance = 100ml/kg/day
- WARM fluids

25



Subcutaneous Fluid Administration

- If IO or IV administration not possible –bird is too weak to withstand catheter placement
- Fluids are very readily absorbed, even in critical birds

26

Use medial flank – natural SC space where leg intersects with body

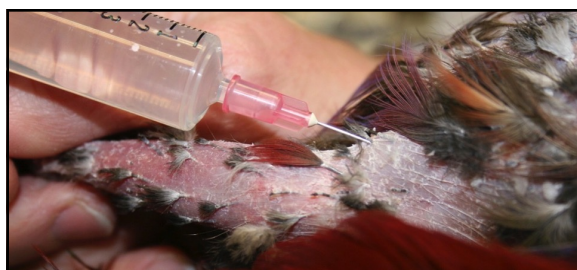

MEDVET

27



28

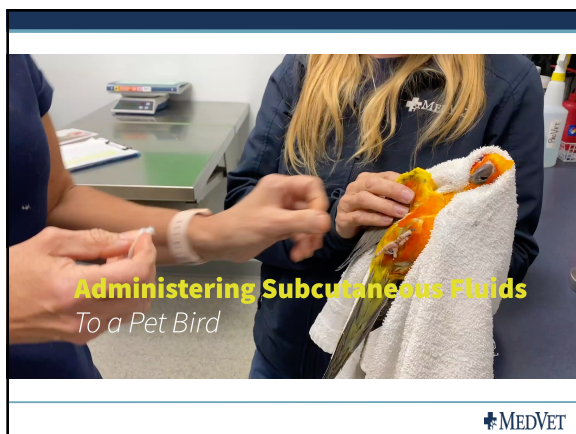


25g needle – no matter size of bird
Larger bore needle will create a bigger hole –fluid leaks
Insert bevel of needle under skin, inject to inflate space

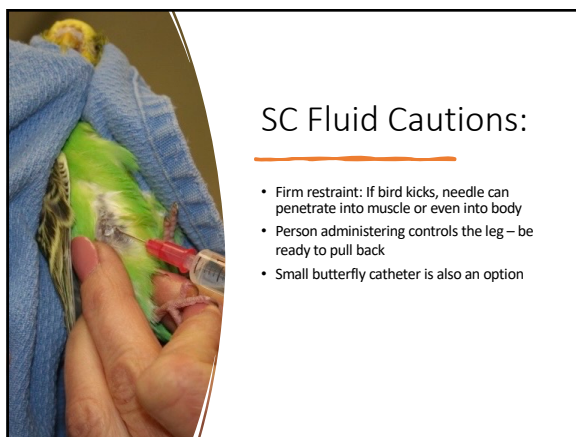
29



30



31



32




33

Dyspnea – Tracheal Obstruction



MEDVET


34



Dyspnea – Lower Respiratory

- Heart Failure
- Pneumonia
- Air sac Compression


35



Dyspnea

- Oxygen
- Furosemide
- Antibiotics

36




Trauma- Hemorrhage

- Broken Blood Feathers
- Beak Fractures

MEDVET

37




Broken Blood Feathers

- Emerging Feathers have rich blood supply
- Can die from blood loss

38

Pull straight out from the base

- Direct Pressure
- Gel foam
- Monitor afterwards!



MEDVET

39



Beak Injury:
Bite wounds
Crash landings

Stop Hemorrhage

- Pressure
- Gelfoam
- Styptic powder
- Silver Nitrate sticks
- Cautery

40



Prognosis depends on location of injury

Beak tip – distal 1/3 will grow back


41




Prognosis depends on location of injury

Distal 1/2: will heal, but blunted

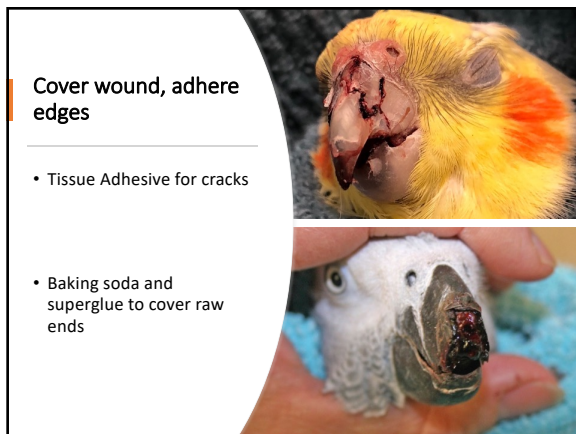
42



43



44



45

Supportive Care

- Assist feed, soft foods
- Pain Medication



MEDVET

46



Refer for more advanced repair

47

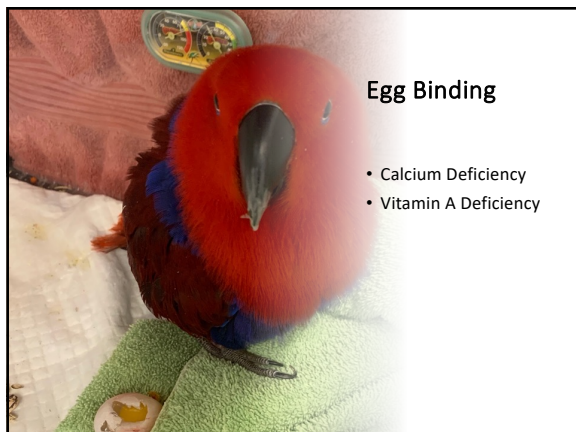Reproductive Emergencies

- Egg Binding
- Cloacal Prolapse

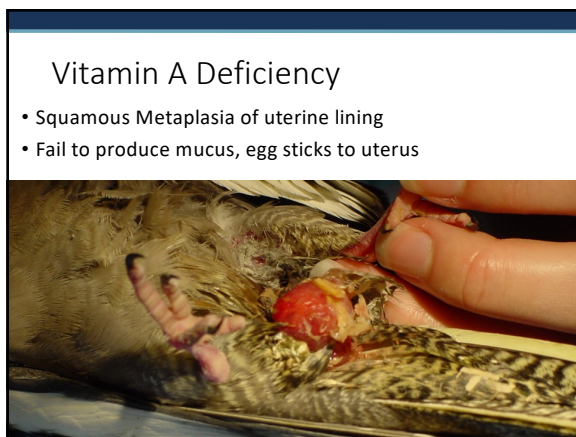


MEDVET

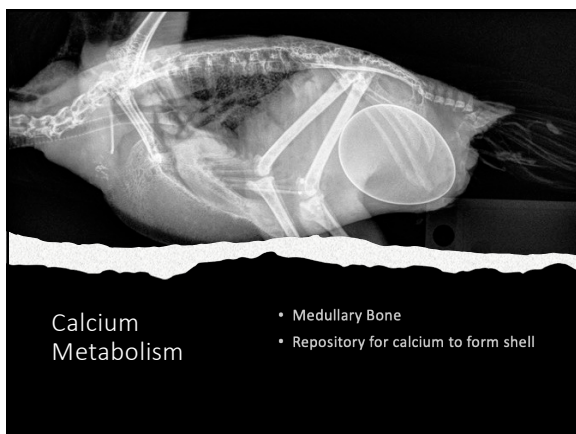
48



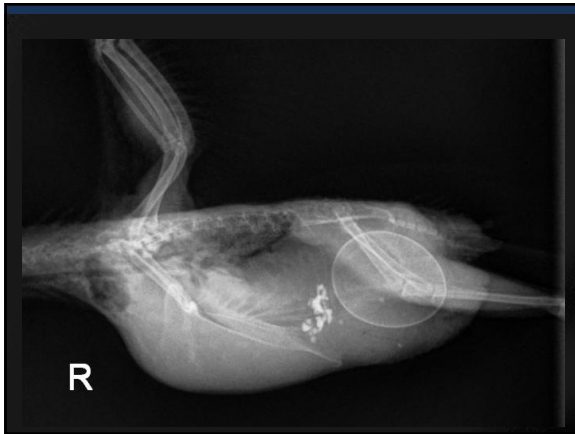49



50



51



52

Clinical Signs - Egg Binding

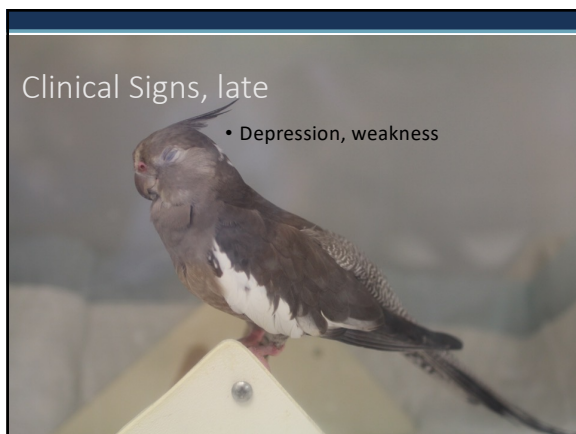- Straining
- Weakness
- Drooped wings
- Wide legged stance
- Rear limb paresis

53

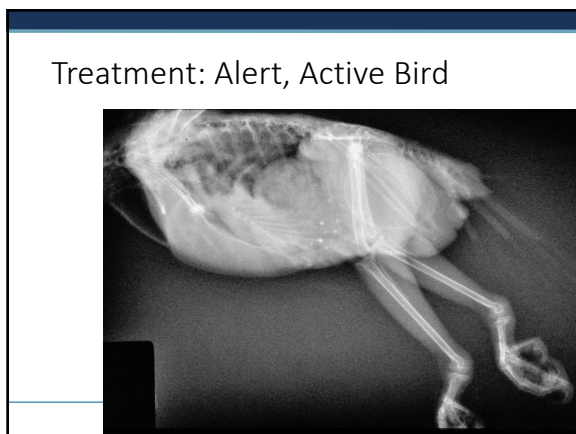Clinical Signs

- Abdominal Distension
- Fecal Staining

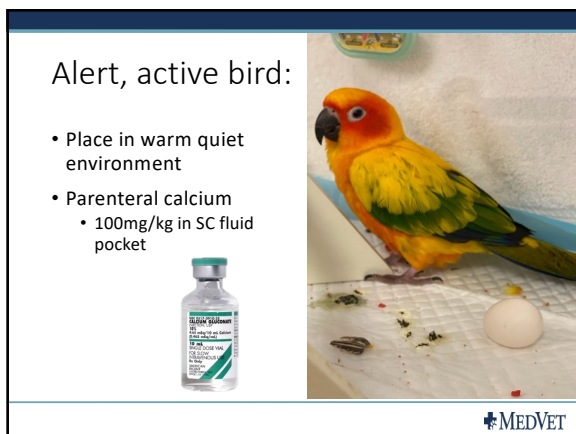
54



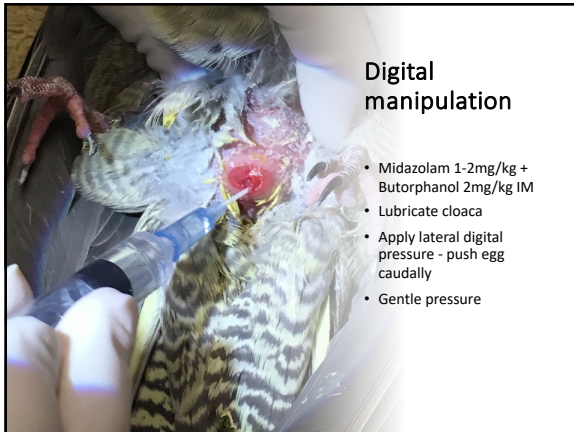
55



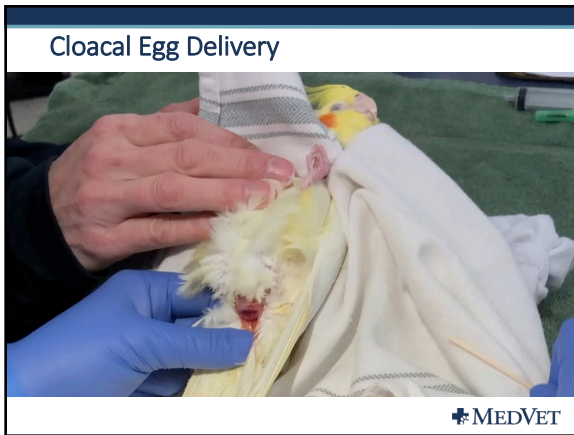56



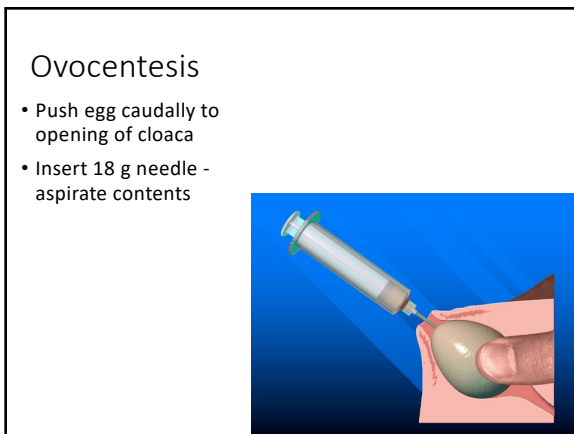
57



58




59



60

Aspirate egg fluids

- Visualize shell
- Aspirate with 18g



61




EGG Delivery
*Collapsing
Via Cloaca*

R

MEDVET

62

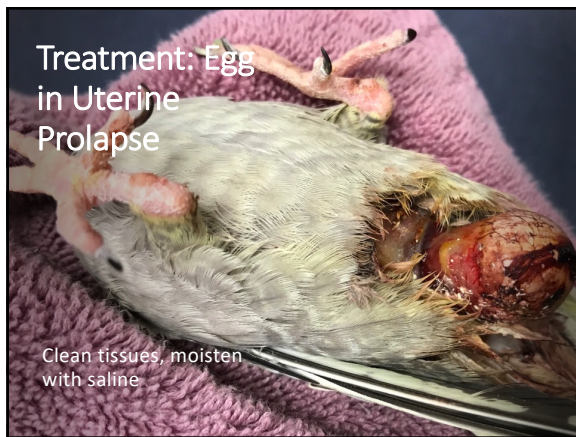- Remove pieces with forceps



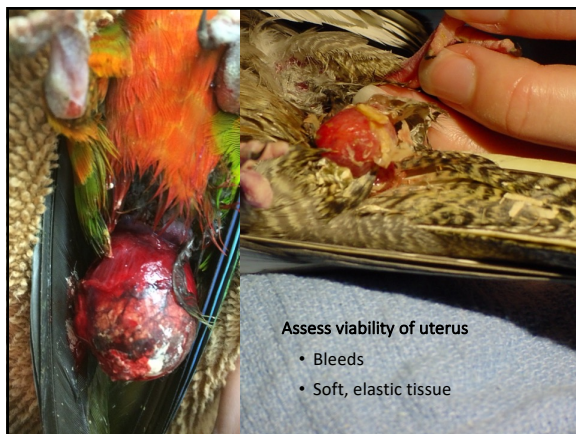63



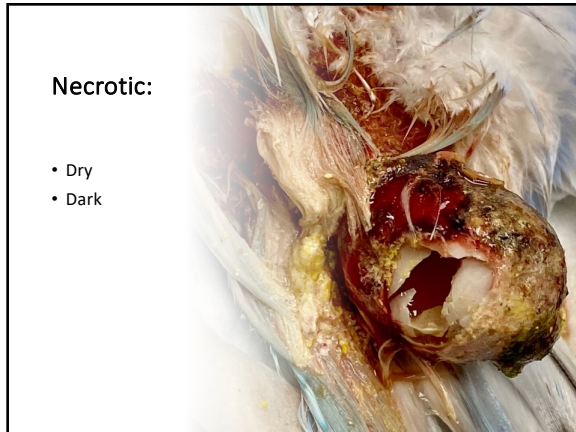
64



65



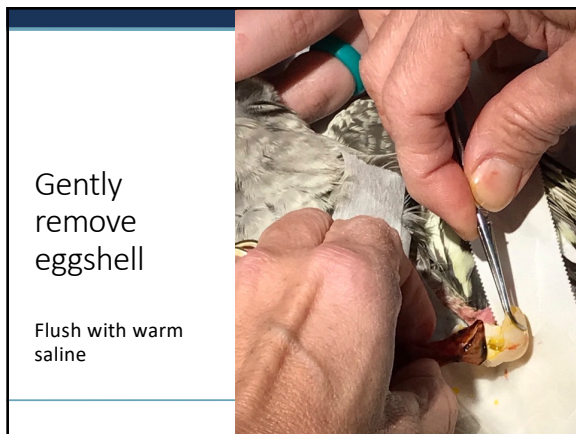
66



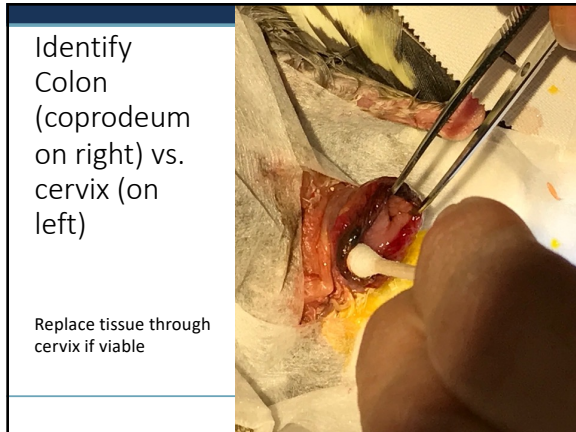
67



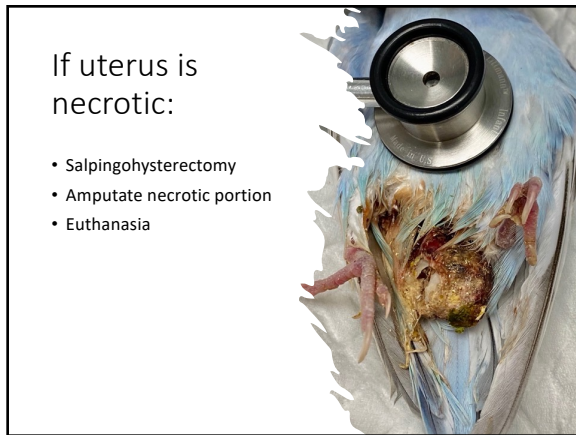
68



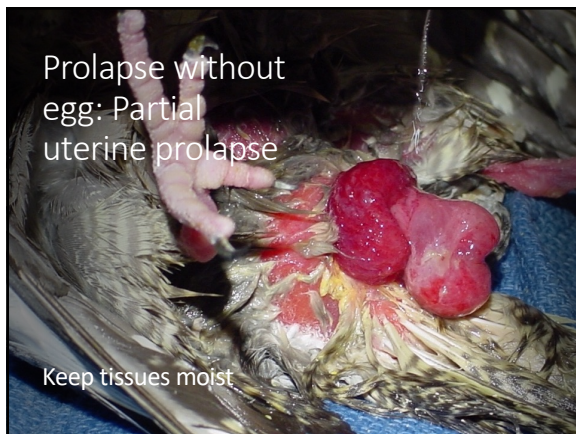69



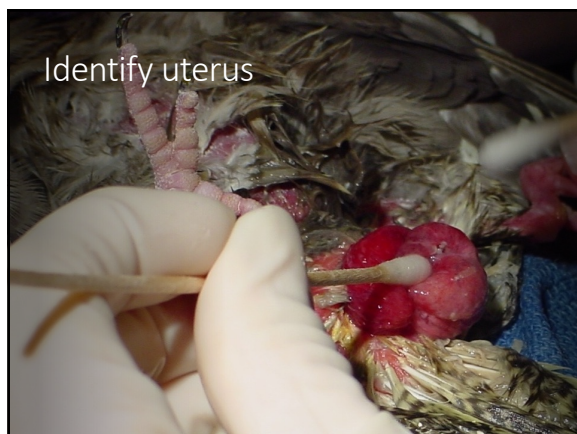
70



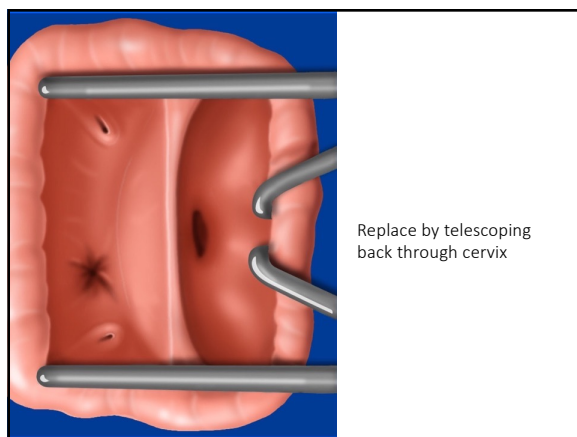
71



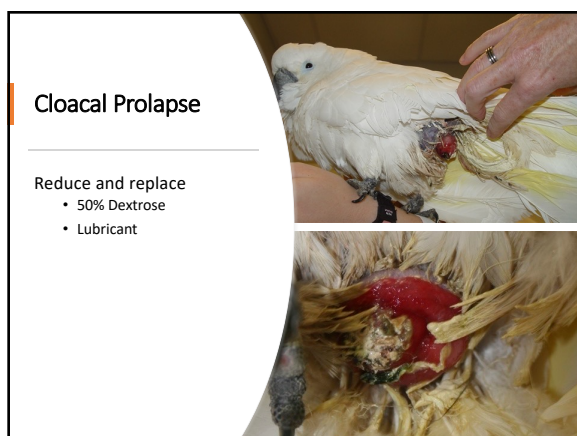72



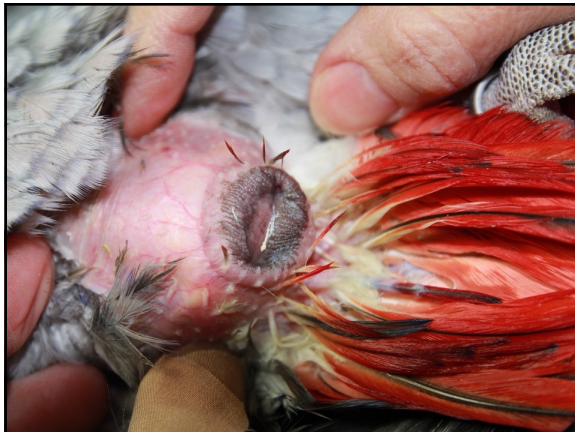73



74



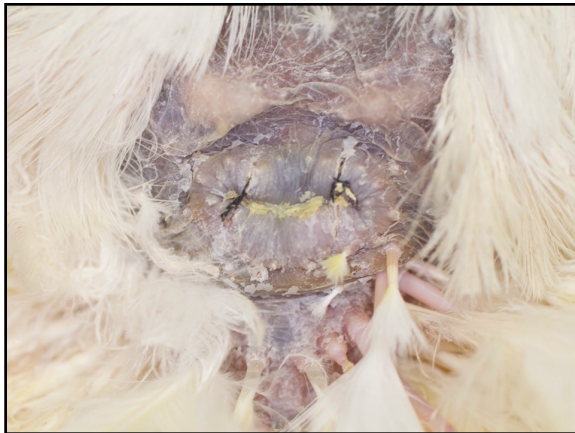75



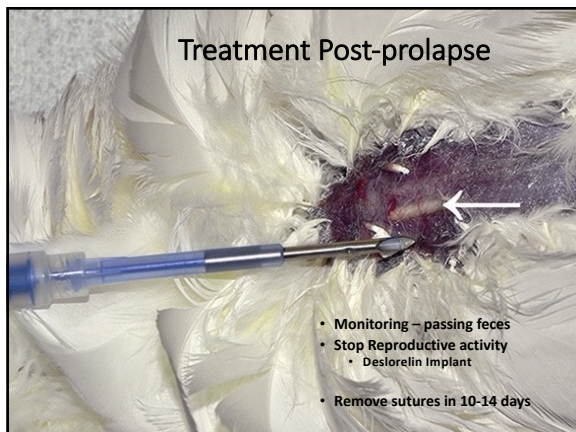
76



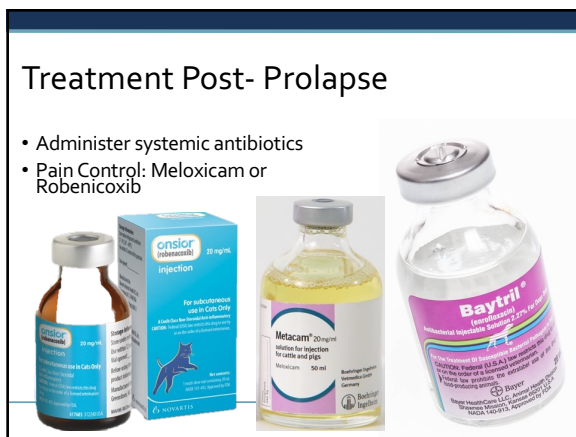77



78



79



80
