Breast Parenchymal Patterns and Their Changes with Age[1]

John N. Wolfe, M.D.

The appearance of the breast parenchyma was studied in 955 women to determine whether it changed with age. It was found that women initially classified as being at either a low risk or a very high risk of cancer do not demonstrate changes in the breast parenchyma pattern with age. However, breasts in young women which exhibit dysplastic changes on the initial examination (QDY) frequently do change, occasionally to a relatively lower-risk category but often to a normal or near-normal appearance. Such changes generally occur between the ages of 35 and 50.

INDEX TERMS: Breast, diseases • Breast Neoplasms, diagnosis

Radiology 121:545–552, December 1976

THE BREAST parenchyma can be regarded as being composed of fat, connective and epithelial elements (which may be seen as dysplasia on the mammogram), and periductal collagenosis (seen as a prominent duct pattern). Aging has a profound influence on dysplastic tissue but not on other types, as can be seen on the mammogram usually between the ages of 30 and 50 and even more between 40 and 50 or at the time of menopause. Since it is possible to predict who will get breast cancer with some degree of certainty on the basis of the pattern of the parenchyma, it is important to know how this pattern changes with age. Other factors which influence the breast parenchyma were

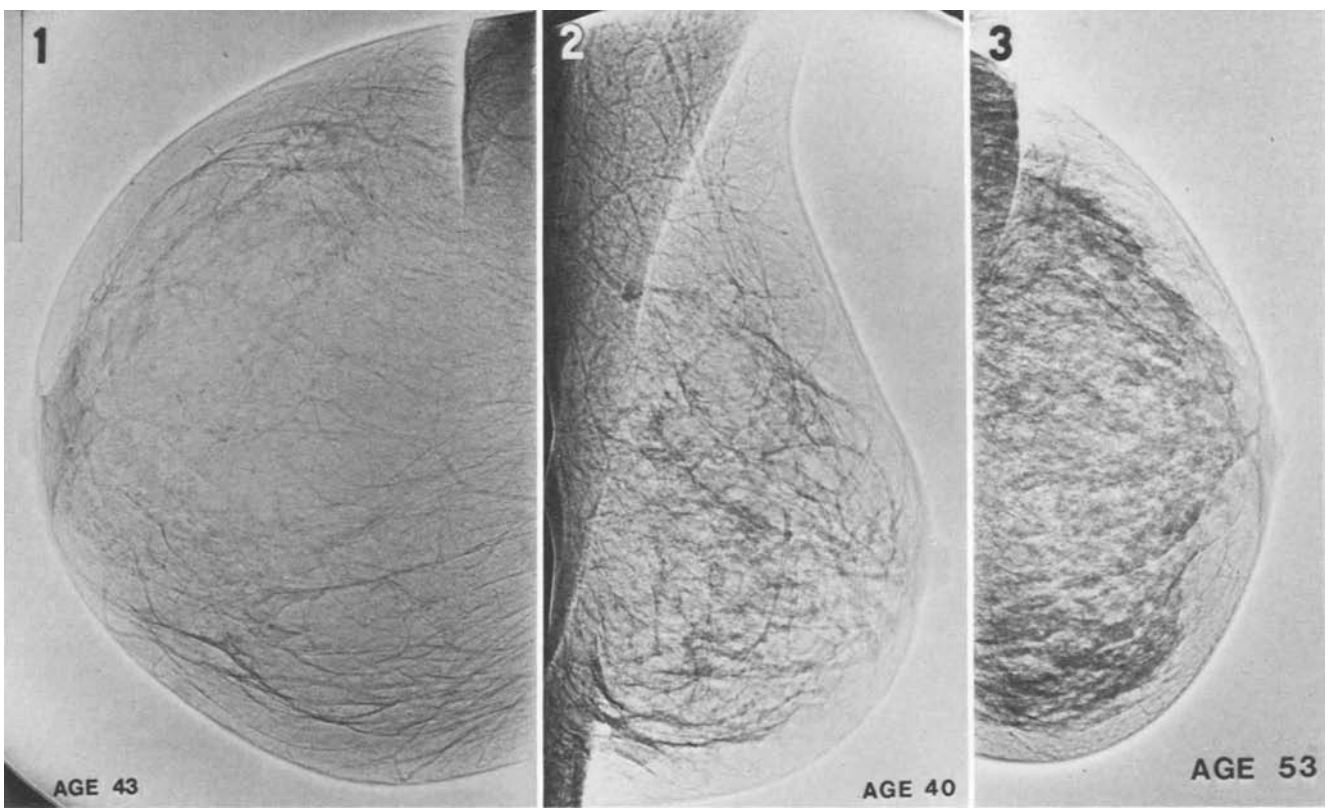

Fig. 1. Classic example of N1 pattern. The breast is composed almost entirely of fat.
Fig. 2. An example of the P1 pattern. Note the prominent ducts in the subareolar area, involving less than one-fourth of the breast.
Fig. 3. Prominent duct pattern involving a large part of the breast, indicating a P2 classification.

[1] From the Department of Radiology, Hutzel Hospital, Detroit, Mich. Presented at the Sixty-first Scientific Assembly and Annual Meeting of the Radiological Society of North America, Chicago, Ill., Nov. 30–Dec. 5, 1975. sjh

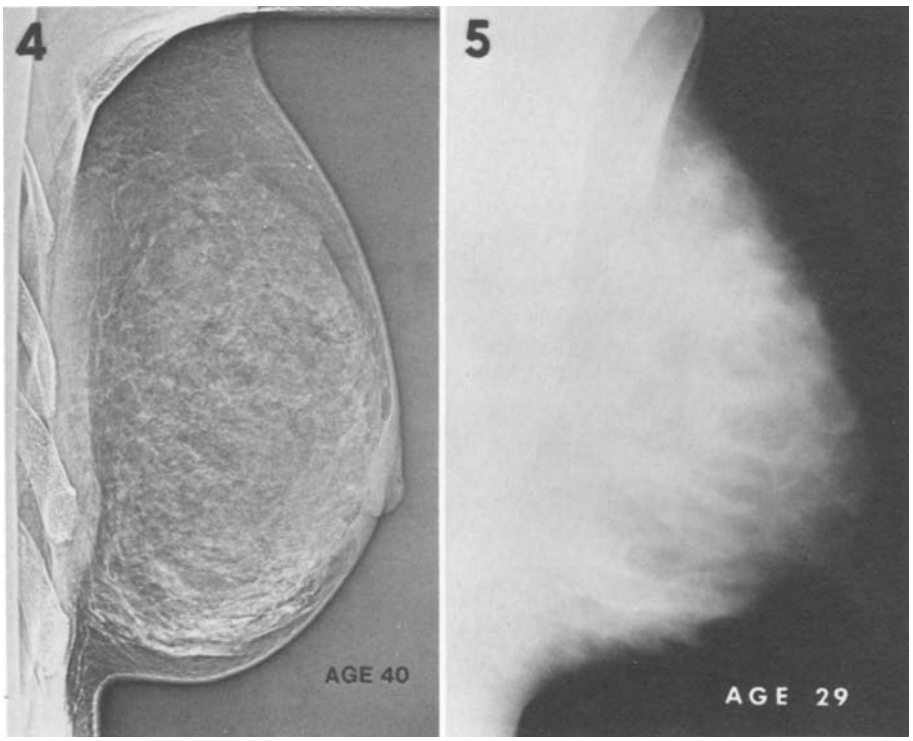

Fig. 4.. Typical appearance of a DY breast. Note the coalescent areas of dysplasia. As the patient ages, these may change to produce a widespread prominent duct pattern.

Fig. 5. Typical appearance of the QDY breast. The breast is quite dense, with ovoid and round areas of fat occupying a considerable portion of the parenchyma. One would expect this breast to change considerably, probably between the ages of 40 and 50, perhaps regressing as far as N1.

Table I: Risk of Breast Cancer Based on Appearance of Breast Parenchyma

Class	Cases No.	Cases %	Carcinomas No.	Carcinomas %	Incidence (%)
N1	2,190	41.4	3	5.36	0.14
P1	1,355	26.0	7	12.5	0.52
P2	1,375	26.0	27	48.21	1.96
DY	364	7.0	19	33.93	5.22
Total	5,284	100.4	56	100.00	1.06

considered, among them birth control pills, externally administered hormones, pregnancy, and thyroid hormones, but nothing was found to affect the parenchyma nearly as much as the aging process.

Background Information

In a previous study of women whose breasts were "normal" on physical examination (1), it was found that with age, "dysplastic changes" decreased and the prominent duct pattern (periductal collagenosis) increased. At first I thought that the pattern represented a hyperplastic change within the breast which existed only occasionally in young women but developed in others as a result of the aging process. It now seems more likely that this pattern, if present, exists at a very early age (teens or early twenties) but often becomes apparent only with the disappearance of overshadowing dysplastic elements.

Having determined that there was a relationship between the prominent duct pattern and aging, I conducted a second survey to find out whether this pattern could be correlated with known breast cancer (2). This study revealed an abnormally high incidence of the prominent duct pattern in women who had breast cancer now or in the past. I therefore reasoned that such a pattern might enable one to predict which women had or would get breast cancer. To see whether this was true, I grouped all female breasts into four patterns, using strict criteria in case selection, classification, and use of follow-up information (3, 4). The four categories were:

N1: This signifies an essentially "normal" breast; the appearance will vary somewhat according to the age of the patient, but ideally it is either composed almost solely of fat or has a so-called "trabeculated appearance" (Fig. 1). In young women, some regions may be more dense than fat, but the most prominent feature is islands of fat, seen as oval and round areas that are relatively radiolucent.

P1 (for *p*rominent duct pattern)*:* Although these breasts are composed chiefly of fat, up to one-fourth of the volume in the subareolar area exhibits cord-like structures or a beaded appearance corresponding to prominent ducts. In some cases a thin band of duct-like structures may be seen extending into one quadrant, typically the upper axillary quadrant (Fig. 2).

P2: The prominent duct pattern occupies more than

Table II: Projected Risk for DY Group by Age

	30–39 yr.			40–49 yr.			50–59 yr.		
	1967–1971	1972	Total	1967–1971	1972	Total	1967–1971	1972	Total
Study population	120	100	220	204	186	390	25	24	49
No. of cancers	5	0	5	9	9	18	5	3	8
Incidence/3 yr.	4.17%	0	2.27%	4.4%	4.8%	4.6%	20%	12.5%	16.3%
Projected risk for remainder of life per 1,000 women*	490	0	239	367	400	383	1,000	625	815

* Based on projected life to age 70

Table III: Distribution of Age at First Examination

Age (yr.)	No.	%
0–19	8	0.84
20–24	27	2.83
25–29	75	7.85
30–34	137	14.35
35–39	181	18.95
40–44	236	24.71
45–49	137	14.35
50–54	74	7.75
55–59	43	4.50
60+	36	3.77
Not known	1	0.10

Table IV: Changes Observed in Parenchymal Patterns From First Examination (R_1) to Second Examination (R_2)

	R_1			R_2	
Class	No.	%		No.	%
N1	166	17.4	→	189	19.8
P1	95	10.1	→	172	18.0
P2	190	20.0	→	352	36.8
DY	504	53.0	→	242	25.3

Table V: Distribution by Age Groups at the Time of the First Examination*

	N1		P1		P2		DY		Row Total	
Age (yr.)	No.	%	No.	%	No.	%	No.	%	No.	%
0–19	2	25	1	13	0	0	5	63	8	100
20–24	6	22	0	0	0	0	21	78	27	100
25–29	18	24	2	3	2	3	53	71	75	100
30–34	33	24	9	7	12	9	83	61	137	100
35–39	34	19	13	7	24	13	110	61	181	100
40–44	31	13	11	5	57	24	137	58	236	100
45–49	18	13	15	11	38	28	66	48	137	100
50–54	10	14	17	23	28	38	19	26	74	100
55–59	4	9	21	49	11	26	7	16	43	100
60+	9	25	6	17	18	50	3	8	36	100
Unknown	1	100	0	0	0	0	0	0	1	100
Total	166	17	95	10	190	20	504	53	955	100

*Some series of percentages add up to 101% because of rounding off of figures.

one-fourth of the breast volume; in its most severe form, all of the parenchyma is involved (Fig. 3).

DY (for *dy*splasia): Much of the breast has a density greater than that of fat, but the prominent duct pattern is absent. In its most severe form, the parenchyma appears rather homogeneous (Fig. 4).

This study and others have demonstrated the necessity of having a fifth classification, *QDY*, which designates the breast of a woman younger than 40 which exhibits a considerable amount of dysplasia and also has islands of fat throughout (Fig. 5). This type of breast has been shown to change (usually with aging) to a lower-risk category, frequently as low as N1. The QDY classification was not used in this study.

The results of these earlier studies show that while cancer may develop in any group, including N1 and P1 (TABLE I), it is possible to survey the population as a whole and choose groups which have a significantly greater risk of getting breast cancer. In the highest-risk group, the likelihood of cancer developing at least six months after a negative radiographic examination is 37 times greater (TABLE I); in other groups, the probability that breast cancer will develop after the age of 40 is conservatively placed at 50% and is likely higher (TABLE II). Equally important, groups have been identified in which the risk of cancer is exceedingly low. All of these data were significant in formulating the present study.

Present Study

All mammographic examinations performed at Hutzel Hospital from the beginning (a total of 15 years) were reviewed and 955 patients who had had at least two examinations at least 5 years apart (range, 5 to 15 yr.; average, 7 yr. 7 mo.) were selected. These cases were pulled from the files and classified as N1, P1, P2, or DY. TABLE III gives the distribution of cases by age at the time of the first examination. As I have found to be the case in a referral-type practice, most patients (72.4%) were between 30 and 49 years of age; however, in all age groups after 25, the numbers are still great enough to give a good idea of breast changes within the study period. Since the patients were all symptomatic, the distribution of classifications does not represent a cross-section of the population.

Table VI: Distribution by Age Groups at the Time of the Second Examination*

Age (yr.)	N1 No.	N1 %	P1 No.	P1 %	P2 No.	P2 %	DY No.	DY %	Row Total No.	Row Total %
0–19	2	25	1	13	1	13	4	50	8	100
20–24	8	30	3	11	2	7	14	52	27	100
25–29	19	25	10	13	13	17	33	44	75	100
30–34	40	29	19	14	33	24	45	33	137	100
35–39	33	18	29	16	54	30	65	36	181	100
40–44	34	14	37	16	109	46	56	24	236	100
45–49	21	15	26	19	74	54	16	12	137	100
50–54	16	22	20	27	35	47	3	4	74	100
55–59	6	14	21	49	13	30	3	7	43	100
60+	9	25	6	17	18	50	3	8	36	100
Unknown	1	100	0	0	0	0	0	0	1	100
Total	189	20	172	18	352	37	242	25	955	100

*Some series of percentages add up to 101% or 99% because of rounding off of figures.

Table VII: Changes in Risk Factor Between the First Examination (R_1) and the Second Examination (R_2)

			R_2 N1 No.	N1 %	P1 No.	P1 %	P2 No.	P2 %	DY No.	DY %
R_1	N1	166	142	86	24	14	0	0	0	0
	P1	95	7	7	86	91	2	2	0	0
	P2	190	0	0	5	3	185	97	0	0
	DY	504	40	8	57	11	165	33	242	48

Table VIII: Changes in Risk Factor

	No.	%
N1 → P1	24	−14
P1 → N1	7	+ 7
P1 → P2	2	− 2
P2 → P1	5	+ 3
DY → N1	40	+ 8
DY → P1	57	+11
DY → P2	165	+33
Total	300	

Table IX: Distribution of DY → N1 Changes by Age Group

Age (yr.)	No.
0–19	0
20–24	3
25–29	5
30–34	10
35–39	6
40–44	7
45–49	4
50–54	4
55–59	1
60+	0
Total	40

Table X: Distribution of DY → P1 Changes by Age Group

Age (yr.)	No.
0–19	0
20–24	2
25–29	4
30–34	6
35–39	9
40–44	23
45–49	8
50–54	4
55–59	1
60+	0
Total	57

Table XI: Distribution of DY → P2 Changes by Age Group

Age (yr.)	No.
0–19	1
20–24	2
25–29	11
30–34	22
35–39	30
40–44	51
45–49	38
50–54	8
55–59	2
60+	0
Total	165

Table XII: Distribution of All Changes by Age Group

Age (yr.)	Total	Changes No.	Changes %	No Changes No.	No Changes %
0–19	8	1	10	7	90
20–24	27	8	30	19	70
25–29	75	24	32	51	68
30–34	137	44	32	93	68
35–39	181	52	29	129	71
40–44	236	88	37	148	63
45–49	137	55	40	82	60
50–54	74	21	28	53	72
55–59	43	5	12	38	88
60+	36	2	6	34	94
Unknown	1	0	0	1	100
Total	955	300		655	

RESULTS

TABLE IV compares the risk classification at the time of the initial study (R_1) and the second examination (R_2). The number of N1 breasts increased only slightly with age, while P1 and P2 increased significantly and DY decreased significantly.

TABLES V and VI show the distribution of patients by age groups at the time of examinations R_1 and R_2. There is very little change in the parenchymal pattern after the age of 50. DY and P2 have an inverse relationship, especially between the ages of 20 and 50.

The direction of change in risk factors is shown in TABLE VII and analyzed in TABLE VIII. N1 changed to P1 in 14% of cases. This does not represent a severe degree of change insofar as risk is concerned; usually it is due to minor degrees of subareolar dysplasia having been observed on the first examination and subsequently disappearing, only to reveal minor involvement of that region with prominent ducts. P1 regressed to N1 in only 7% of cases, due to a variation of judgment that is inherent in the

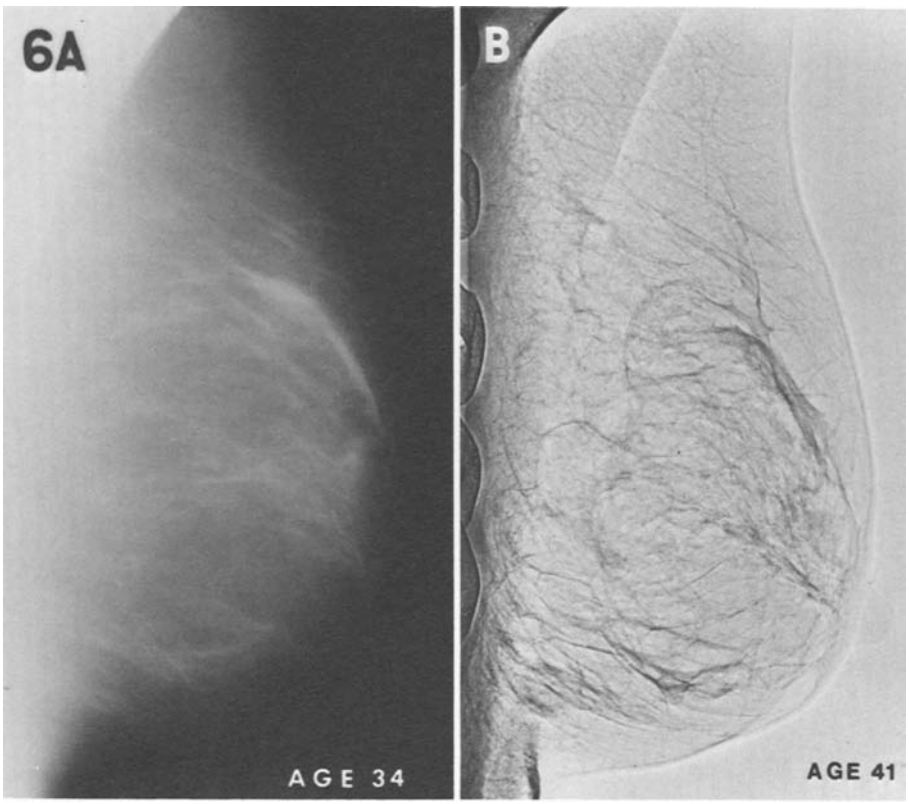

Fig. 6. Radiographs taken 7 years apart. No changes have occurred in the parenchyma, which is basically composed of fat. Both studies would be considered to represent an N1 classification.

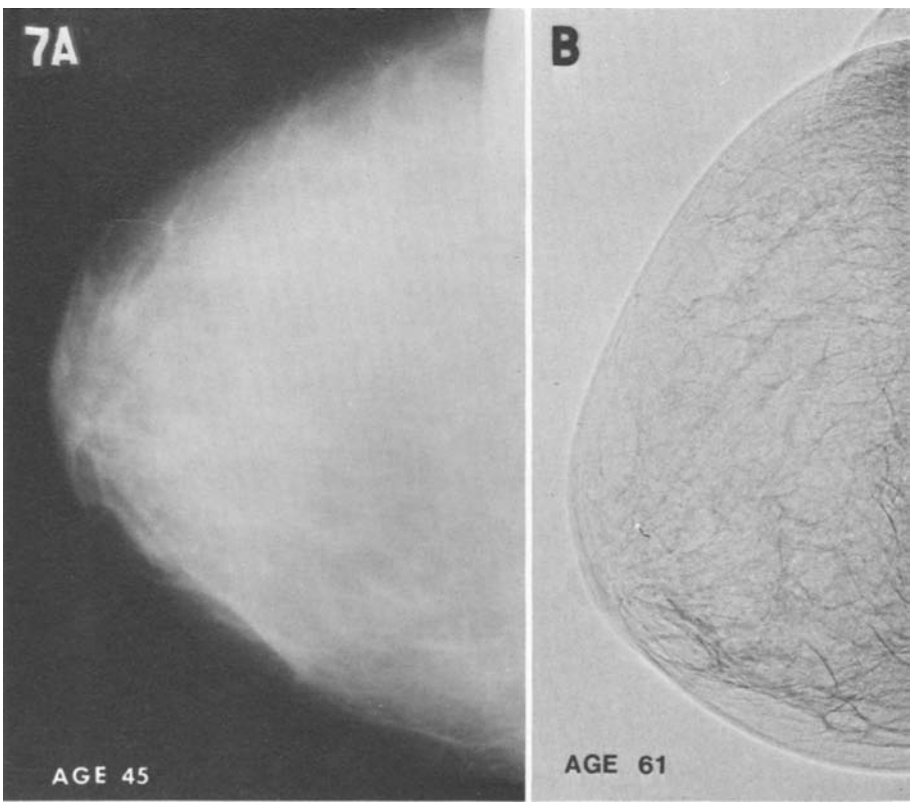

Fig. 7. Radiographs taken 16 years apart. Initially the breast is quite dense, with some suggestion of a cord-like pattern in the subareolar area, indicating a P1 classification; the subsequent examination shows that this is correct.

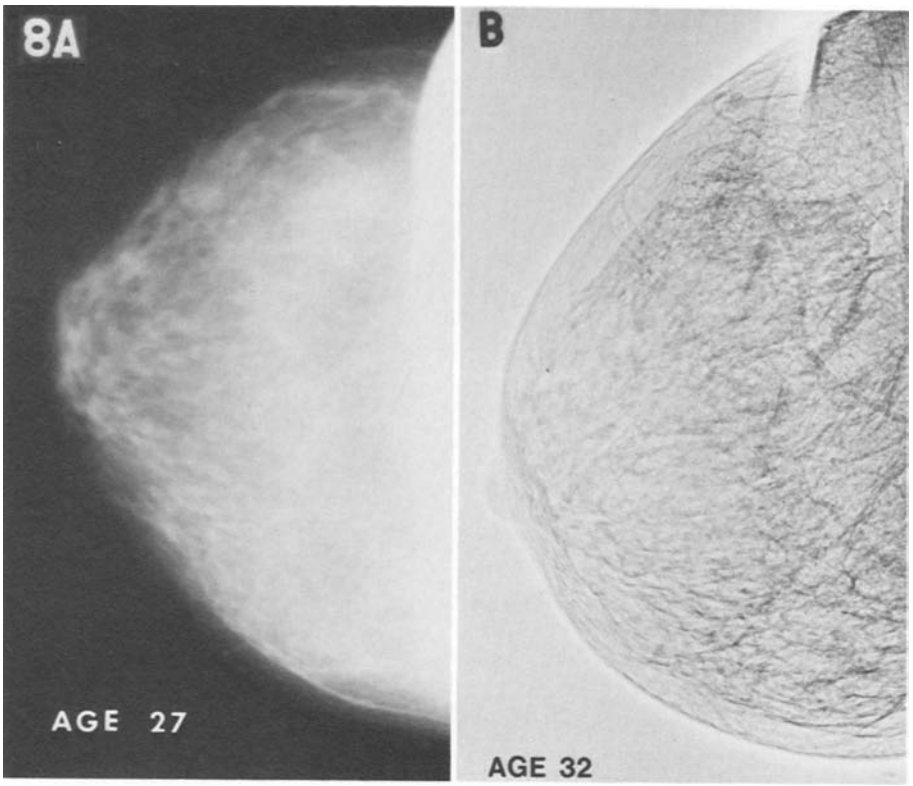

Fig. 8. Radiographs taken 5 years apart. Although the patient was only 27 at the time of the initial examination, the P2 pattern persists. The later study reveals only some diminution in the overlying dysplasia. One would not expect to see a significant change in the appearance of the breasts for the rest of the patient's life.

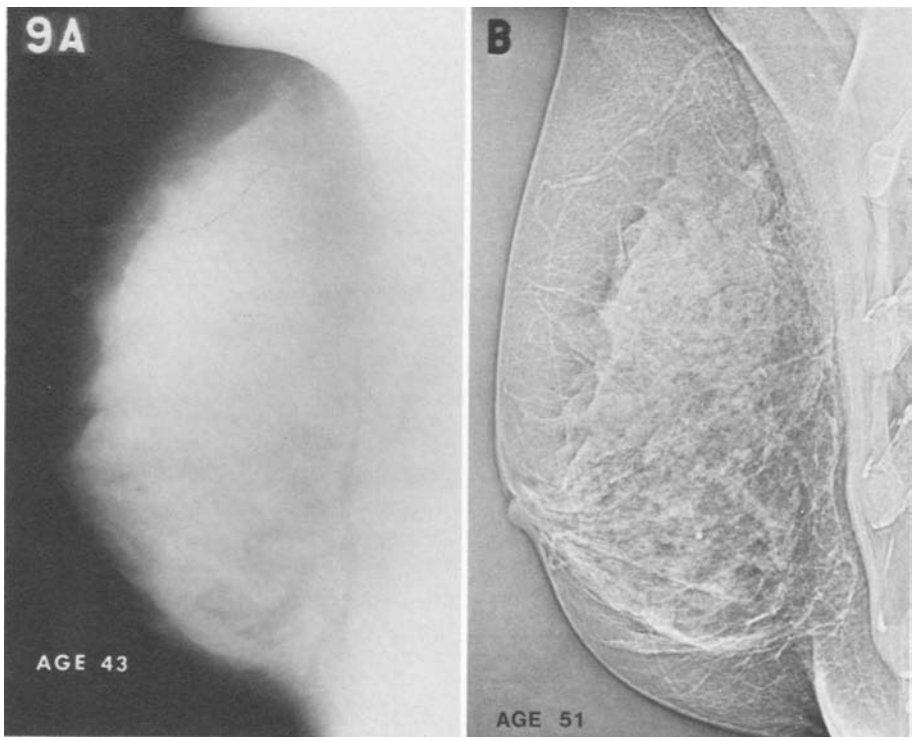

Fig. 9. Radiographs taken 8 years apart reveal a persistent DY appearance. On the initial study at the age of 43, the coalescent areas of dysplasia are indicative of the DY classification. Although some duct pattern is beginning to develop in the subareolar area, at the age of 51 there are still coalescent areas of dysplasia and the classification should remain DY.

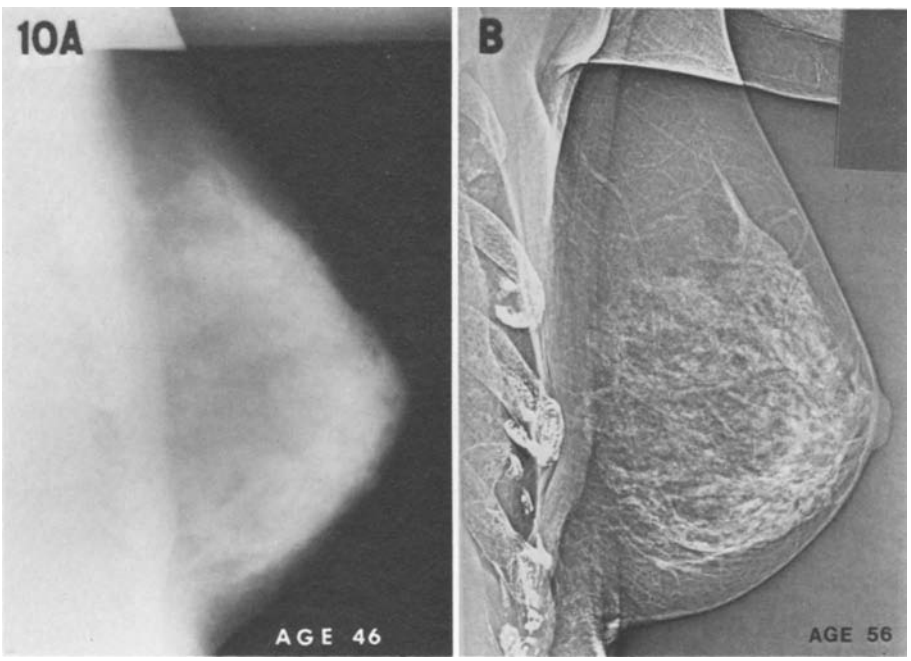

Fig. 10. DY often evolves into P2, as shown in this case. On the initial examination, coalescent areas of dysplasia are noted and the classification is DY. Ten years later the prominent duct pattern is very apparent.

classification process: at one time one may classify a few linear subareolar densities as a very minimal duct pattern (P1), while at another time the judgment might be that the breast is within the limits of N1. P1 changed to P2 twice, again representing the middle ground of classification where the two groups merge with regard to the severity of involvement and at any given time one may make a judgment of P1 or P2. It is remarkable that it occurred so seldom. P2 regressed to P1 in 2.6% of cases for the same reason. The significant changes occurred in the DY group, of whom only 48% were still DY at the time of the second study. The greatest change was from DY to P2 (33%), but significant numbers also regressed to a much lower risk factor (11% to P1 and 8% to N1). Thus a total of 274 changes (28.7%) involved an improvement and 26 represented deterioration, with the latter being considered errors in observation or a result of the "gray area" of classification: I am firmly convinced that the risk factors themselves do not actually increase. It is important that this deterioration accounted for only 2.7% of all cases, indicating a high degree of reliability in the classification system.

The distribution of the changes in risk factors by age group in the DY patients is shown in TABLES IX–XI. Changes from DY to N1 occur at a relatively young age, frequently less than 40, while changes from DY to P1 tend to occur in slightly older women and changes from DY to P2 are frequently observed in even older patients.

The distribution of all changes is shown in TABLE XII. The frequency of change is slightly higher between the ages of 40 and 50 than in other age groups and significantly lower in women 55 or older.

To summarize:

(*a*) It is unusual for a breast initially classified as N1, P1, or P2 to change. If the initial classification is unequivocal, the parenchyma will probably never change (Figs. 6–8).

(*b*) Breasts initially classified as DY have a tremendous propensity for change, most frequently to P2; however, significant numbers change to P1 or N1 (Figs. 9 and 10).

(*c*) A QDY classification is needed in order to categorize the breasts of women younger than 40; most likely they will change to a low-risk group later in life. QDY breasts are best described as being between N1 and DY and are characteristically rather dense with discrete islets of fat throughout (Fig. 11).

CONCLUSION

I believe that it is possible to predict with considerable accuracy which women are likely to get breast cancer solely on the basis of the appearance of the parenchyma. The question is whether this appearance changes with age. My studies show that breasts initially classified as being in a low-risk category or in a higher-risk group such as P2 never change. Breasts containing dysplastic tissue (DY) frequently change, in most cases to P2 (which is still a high-risk group) but also in a significant number of cases to P1 or N1. This change occurs most often between the ages of 35 and 50.

REFERENCES

1. Wolfe JN: Mammography: report on its use in women with

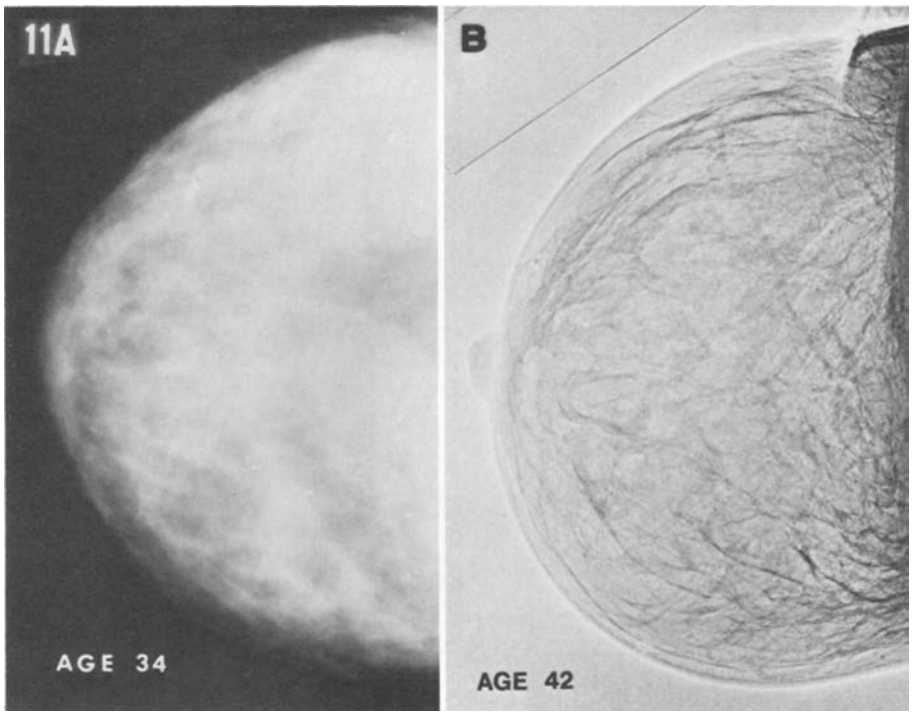

Fig. 11. Radiographs taken 8 years apart. On the initial study there are coalescent areas of dysplasia, but also multiple ovoid and round areas of fat which would indicate a QDY classification. On the second study, most of the dysplasia has disappeared and the classification reverts to N1.

breasts abnormal and normal on physical examination. Radiology **83:**244–254, Aug 1964

2. Wolfe JN: Mammography: ducts as a sole indicator of breast carcinoma. Radiology **89:**206–210, Aug 1967

3. Wolfe JN: Risk for breast cancer development determined by mammographic parenchymal pattern. Cancer **37:**2486–2492, May 1976

4. Wolfe JN: Breast patterns as an index of risk for developing breast cancer. Am J Roentgenol **126:**1130–1139, Jun 1976

Department of Radiology
Hutzel Hospital
432 E. Hancock Ave.
Detroit, Mich. 48201