OPEN

Nipple-Sparing Mastectomy and Ptosis: Perforator Flap Breast Reconstruction Allows Full Secondary Mastopexy with Complete Nipple Areolar Repositioning

Frank J. DellaCroce, M.D.
Craig A. Blum, M.D.
Scott K. Sullivan, M.D.
Alan Stolier, M.D.
Chris Trahan, M.D.
M. Whitten Wise, M.D.
Dustin Duracher, B.S.

New Orleans, La.

Background: Patients with moderate to severe ptosis are often considered poor candidates for nipple-sparing mastectomy. This results from the perceived risk of nipple necrosis and/or the inability of the reconstructive surgeon to reliably and effectively reposition the nipple-areola complex on the breast mound after mastectomy.
Methods: A retrospective review identified patients with grade II/III ptosis who underwent nipple-sparing mastectomy with immediate perforator flap reconstruction and subsequently underwent a mastopexy procedure. The mastopexies included complete, full-thickness periareolar incisions with peripheral undermining around the nipple-areola complex to allow for full transposition of the nipple-areola complex relative to the surrounding skin envelope.
Results: Seventy patients with 116 nipple-sparing mastectomies met inclusion criteria. The most common complications were minor incisional dehiscence (7.7 percent) and variable degrees of necrosis in the preserved breast skin (3.4 percent) after the initial mastectomy. There were no cases of nipple-areola complex necrosis following the secondary mastopexy.
Conclusions: The authors demonstrate that full mastopexy, including a complete full-thickness periareolar incision and nipple-areola complex repositioning on the breast mound, can be safely performed after nipple-sparing mastectomy and perforator flap breast reconstruction. The underlying flap provides adequate vascular ingrowth to support the perfusion of the nipple-areola complex despite complete incisional interruption of the surrounding cutaneous blood supply. These findings may allow for inclusion of women with moderate to severe ptosis in the candidate pool for nipple-sparing mastectomy if oncologic criteria are otherwise met. These findings also represent a significant potential advantage of autogenous reconstruction over implant reconstruction in women with breast ptosis who desire nipple-sparing mastectomy. (*Plast. Reconstr. Surg.* 136: 1e, 2015.)
CLINICAL QUESTION/LEVEL OF EVIDENCE: Therapeutic, IV.

Nipple-sparing mastectomy has gained traction as a surgical option for women with active breast cancer and those seeking prophylactic mastectomy. Nipple-sparing mastectomy, in simplest terms, is a skin-sparing mastectomy that also preserves the nipple-areola complex as a component of the retained skin envelope. The goal of nipple-sparing mastectomy is preservation of structure and form without compromising oncologic objectives.[1] The same logic that drives breast conservation protocols (lumpectomy/irradiation) propels the concept of nipple-sparing mastectomy forward. With the growing sophistication of breast reconstruction techniques and demand for high-quality aesthetic outcomes, it is clear why nipple-sparing mastectomy continues to increase in popularity.

From the Center for Restorative Breast Surgery; and St. Charles Surgical Hospital.
Received for publication January 6, 2015; accepted January 28, 2015.

DOI: 10.1097/PRS.0000000000001325

Disclosure: *The authors have no financial interest to declare in relation to the content of this article.*

Nipple-sparing mastectomy, in modern convention, is to be clearly differentiated from the "subcutaneous mastectomy" popularized in the 1970s for fibrocystic disease. These procedures were performed with a technical bias toward cosmesis and less concern for removing a maximum amount of breast tissue. Subcutaneous mastectomy may allow for gross breast tissue to be left behind intentionally to improve the cosmetic result and/or to minimize the risk of necrosis of the skin/nipple.[2] Modern nipple-sparing mastectomy, whether for prophylactic or therapeutic intent, is performed with the goal of safely removing all grossly visible breast tissue and is an extension of the well-accepted standard skin-sparing mastectomy. With careful incision placement and appropriate technique, nipple-areola complex survival is extremely predictable.[3] Stolier and Levine[3] emphasize the importance of preserving major perforating vessels while performing nipple-sparing mastectomy, most notably the second intercostal perforator. Elevating the skin flaps in the plane between the subcutaneous fat and the glandular tissue is essential. The thickness of the flap is determined by the location of this plane rather than any preset planning intent or measurement. Careful technique and prudent incision placement can lead to what can only be thought of as a criterion standard in reconstructive outcomes when paired with an immediate reconstruction.

Although no prospective trials exist, it has been shown repeatedly that nipple-sparing mastectomy may be safely performed in carefully selected patients.[4] Hartmann et al. demonstrated that the risk of developing a primary invasive tumor within the nipple-areola complex after prophylactic nipple-sparing mastectomy in moderate- or high-risk patients is very low.[5] More recently, Maxwell et al. reviewed published reports of 1868 nipple-sparing mastectomies performed for breast cancer treatment and found that only three local recurrences (0.16 percent) within the nipple-areola complex have been reported.[6]

Despite these and other reports demonstrating the oncologic safety of nipple-sparing mastectomy, its limitations are recognized. Recent publications continue to define the oncologic contraindications to nipple-sparing mastectomy, including inadequate distance from the tumor to the nipple, large tumor size, and positive lymph node status.[7]

The anatomical contraindications to nipple-sparing mastectomy remain less well defined. It has been suggested that large breast size and ptosis are contraindications because of difficulty managing the large skin envelope and the potential for ischemic complications.[8] Patients with moderate to severe ptosis are often considered poor candidates for nipple preservation because of the perceived risk of nipple necrosis and/or the inability of the reconstructive surgeon to effectively reposition the nipple-areola complex on the breast mound. Several potential strategies exist for treating the patient with large, ptotic breasts who desires nipple-sparing mastectomy and is otherwise an appropriate candidate for sparing the nipple. These include a staged approach with a mastopexy, reduction followed by nipple-sparing mastectomy, and mastopexy at the time of mastectomy.[9–11]

Spear et al. published a series of 15 patients (24 breasts) who underwent breast reconstruction using a staged nipple-sparing mastectomy following mastopexy or reduction.[9] The authors suggest offering the staged approach to nipple-sparing mastectomy to patients with moderately large or ptotic breasts, but they felt it might not be suitable for the very large or ptotic breast. This approach may be considered for patients undergoing mastectomy for prophylactic indications, but active breast cancer demands a more efficient protocol and completion of the mastectomy without unreasonable delay. In addition, this requires two separate surgical procedures to accomplish the mastectomy with associated independent recovery time, anesthesia risk, hospitalization, and overall added cumulative expense. The publication by Spear et al. on this topic does, however, support the position of offering nipple-sparing mastectomy, when appropriate otherwise, to women who have undergone mastopexy or breast reduction in the past with associated existing periareolar incisional scar lines.

Other authors have described performing mastopexy at the time of nipple-sparing mastectomy; however, this practice may lead to ischemia of the nipple-areola complex and the surrounding skin envelope.[10,11] Because these mastopexy techniques require the maintenance of dermal continuity with the surrounding skin envelope, the amount of nipple-areola complex movement is limited and the blood supply is tenuous.

To address these limitations, we hypothesized that the nipple could be moved based solely on vascular contributions from the underlying perforator flap and that a full-thickness periareolar incision could be safely performed without necrosis of the nipple. This would allow tremendous latitude in the shaping of the breast and nipple height positioning. Our technique for secondary

mastopexy after nipple-sparing mastectomy and immediate perforator flap reconstruction is subsequently described and our experience with an associated 116 nipple-sparing mastectomies in 70 patients is reviewed.

PATIENTS AND METHODS

We retrospectively reviewed the charts of all patients in whom nipple-sparing mastectomy and immediate perforator flap breast reconstruction was performed in our center. We then identified the patients who later underwent a mastopexy procedure that included a complete periareolar incision with wide-field peripheral undermining for nipple-areola complex repositioning. Patients who underwent crescent mastopexy procedures or minor lower pole skin excisions were excluded.

Charts were reviewed for patient age, body mass index, indication, incision placement for nipple-sparing mastectomy, *BRCA* positivity, perforator flap selection, and mastectomy weight. The degree of premastectomy ptosis was determined by evaluating patient photographs (Table 1) and graded according to the Regnault classification.[12] Medical/surgical history and smoking history were also examined. Charts were further reviewed for postmastectomy and postmastopexy complications, including flap loss, nipple-areola complex necrosis, mastectomy skin flap necrosis, incisional dehiscence, infection, and hematoma.

Operative Technique

Patients underwent mastopexy, on average, 185 days after reconstruction. Patients were scheduled for mastopexy at their discretion, but none were scheduled sooner than 3 months after reconstruction to allow adequate time for overall recovery. At their preoperative office visit, the ideal nipple position was identified and marked. The nipple-areola complex was typically marked for a reduction to 38 to 42 mm, when required, and depending on patient preference. Various skin incision patterns, ranging from "Wise patterns" to vertical lifts, were designed depending on the degree of ptosis and where skin needed to be resected to achieve the desired modification of breast shape. Under general anesthesia, periareolar incisions are carried out along presurgical markings. The remaining breast incisions are then undertaken, as necessary, and the skin, within the boundaries of the incisions and around the nipple-areola complex, is deepithelialized. In larger breasts, or those with greater ptosis, this results in a dermal "platform" around the retained nipple-areola complex. In smaller breasts, or those with less ptosis, the dermal "platform" is less substantial, as entry through the dermis into the subcutaneous plane laterally is often necessary at the lateral borders of the nipple-areola complex. Although retention of this dermal platform around the nipple-areola complex may carry benefit in terms of blood supply, it was not found to be essential. Full-thickness incision is then carried out with electrocautery through the dermis at the interface of the dermal platform (or the nipple-areola complex) and the incisional skin edge. This allows entry into the subcutaneous plane and undermining of the breast skin over the underlying perforator flap. This is continued, to whatever degree necessary, for proper breast/flap shape modification, flap size reduction, scar release, and, ultimately, nipple-areola complex/breast mound ascent. The breast skin is then redraped, and the nipple-areola complex is exteriorized and inset into position (Fig. 1).

Table 1. Degree of Premastectomy Ptosis

Ptosis Grade	No.
I	3
II	100
III	10

RESULTS

We identified 70 women who underwent 116 NSMs between January 2011 and June 2013 that met the inclusion criteria. The average patient age was 49.6 (range 34 to 66). The average body mass index was 26.25 kg/m^2(range 19-38.6 kg/m^2). There were no active smokers at the time of mastectomy though 20 patients were former smokers. Nine patients had hypertension, six had hypothyroidism, six had asthma, and one had diabetes. Three patients had experienced massive weight loss, two following bariatric surgery and one via dietary modification alone (Table 2).

Nineteen patients were BRCA positive, 26 were BRCA negative, and 25 were untested. Eighty-four mastectomies were prophylactic and 32 were therapeutic (72.4 and 27.6 percent respectively). One hundred breasts had grade II ptosis while 10 had grade III ptosis. The most common incision for NSM was a "6 o'clock" vertical design (n= 98), followed by a lateral incision (n = 16) and an inframammary pattern (n = 2). Immediate breast reconstruction was carried out with 62 DIEP flaps and 40 SGAP flaps. Multicomponent "stacked" flap techniques

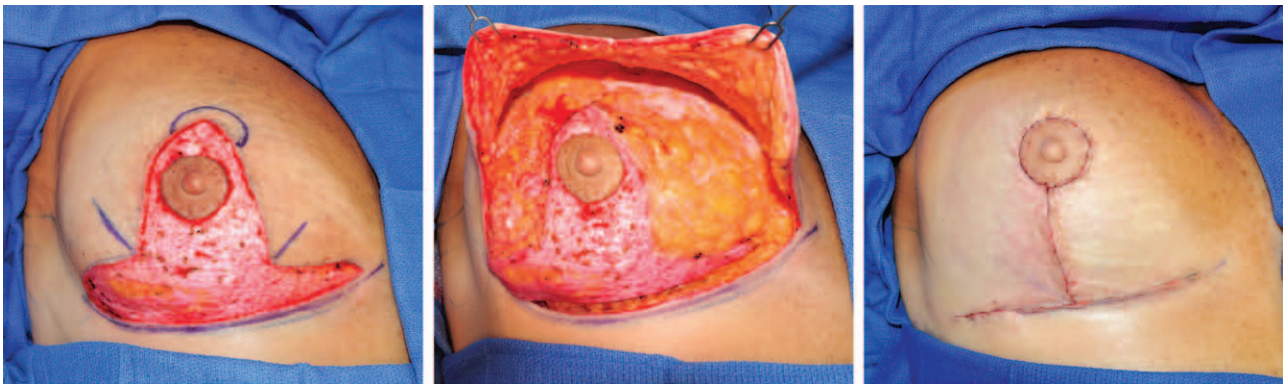

Fig. 1. Skin around the reduced nipple-areola complex is deepithelialized (*left*). The skin envelope is elevated over the flap as necessary and shape/size is modified as desired (*center*). Closure is completed with requisite nipple-areola complex inset position (*right*).

Table 2. Patient Demographics

Characteristic	Value
Mean age, yr	49.6
Mean BMI, kg/m^2	26.25
Former smokers	20
Nonsmokers	50

BMI, body mass index.

Table 3. Mastectomy Data

Characteristic	Value
Indications, no.	
Therapeutic	32
Prophylactic (BCRA-positive, n = 38)	84
Incision type (per breast), no.	
6-o'clock vertical	98
Lateral	16
Inframammary fold	2
Average mastectomy weight, g	429

were also used including stacked DIEP flaps and stacked DIEP + SGAP flaps (13, 14). Mastectomy weights averaged 492.25g (range 133g to 877g) (Table 3). Eight breasts had undergone prior lumpectomy and five of these had received post lumpectomy radiation. One patient had undergone previous breast reduction with a Wise pattern incisional design.

There were 16 breast-related complications; all followed the initial mastectomy, and included nine partial incisional dehiscences, four cases of partial mastectomy flap necrosis, and three hematomas that required operative exploration. There were two flaps with fat necrosis requiring secondary flaps for volume replacement. There were no flap failures (Table 4). After surgical débridement and/or local wound care, all mastectomy flap wounds healed successfully. All patients enjoyed an improvement in their nipple position and/or degree of ptosis (Figs. 2 and 3). Patient satisfaction was high in the studied population, including those patients with grade III ptosis and/or large breasts. All patients reported a willingness to undergo the procedure again based on their satisfaction with their ultimate outcomes, including those patients who experienced minor complications following mastectomy.

Table 4. Complications

Complication	No. (%)
Partial incisional dehiscence	9 (7.7)
Partial mastectomy flap necrosis	4 (3.4)
Hematoma	3 (2.5)
Fat necrosis	2 (1.5)
Flap failure	0 (0)

DISCUSSION

When considering reconstruction in patients with moderate-sized breasts and little to no ptosis, the plastic surgeon need only refill the skin envelope with a prosthetic implant or vascularized soft-tissue (flap) to produce a breast with maximum aesthetic potential. For the mastectomy candidate who presents with significant breast ptosis, the plastic surgeon faces a reconstructive dilemma. Once mastectomy is performed, the underlying blood supply to the preserved nipple-areola complex is eliminated, and it survives beyond that point based only on perfusion from the surrounding skin. How then can the nipple-areola complex be elevated to the desired location on the breast mound when its underlying blood supply has been removed? Logically, this substantially limits options for

Fig. 2. A 42-year-old woman with a strong family history of breast cancer and grade III ptosis before bilateral nipple-sparing mastectomy with the 6-o'oclock vertical incision pattern and immediate DIEP flap breast reconstruction (*left*). After second-stage mastopexy with improved breast shape and nipple position (*right*).

repositioning. Interrupting the blood supply from the surrounding native breast skin with an incision around the full circumference of the nipple-areola complex would suggest a strong likelihood of resultant nipple-areola complex necrosis. However, our work with perforator flaps and secondary nipple-areola complex repositioning has shown that it is possible to safely create a full-thickness, complete periareolar incision with wide-field peripheral skin undermining around a preserved nipple-areola complex after nipple-sparing mastectomy without nipple-areola complex necrosis. Our technique is based on the fundamental plastic surgery principles that lead to graft survival. The process by which skin or other grafts "take" is a series of physiologic occurrences known as imbibition, inosculation, and ingrowth.[15] For the purposes

Fig. 3. A 45-year-old woman with *BRCA* mutation and grade II ptosis before bilateral prophylactic nipple-sparing mastectomy and immediate superior gluteal artery perforator flap breast reconstruction (*left*). After second-stage mastopexy and reduction with associated improved breast shape and nipple position (*right*).

of correlation to our experience, ingrowth is the most essential of these phenomena. Through our large experience with immediate perforator flap breast reconstruction and nipple-sparing mastectomy, we have discovered that the uptake of blood supply by the tissue of the preserved nipple-areola complex from an underlying well-perfused flap is adequate to support the viability of the nipple-areola complex when the surrounding contributions of the skin are interrupted with a full-thickness incision.

Because of this robust nipple-areola complex revascularization, it is possible to completely reposition the preserved nipple-areola complex in a manner differing very little from a routine mastopexy. This completely frees the reconstructive surgeon to modify the breast shape, size, and nipple-areola complex position at the time of

second-stage revision without trepidation. It further removes the "contraindication" of even grade III ptosis from the selection criteria when consulting with patients who desire nipple-sparing mastectomy and are otherwise proper candidates.[7] This advancement allows use of various skin resection patterns as would be performed in a routine mastopexy or breast reduction. The skin flaps may be widely undermined over the perforator flap, with the nipple-areola complex left atop it with a fully adequate blood supply. This offers tremendous latitude in nipple-areola complex repositioning. This powerful tool is a substantial advantage that any well-perfused flap reconstruction has over implant-based breast reconstruction. As a result, this adds another variable when weighing the advantages and disadvantages of implant reconstruction versus flap-based breast reconstruction for those who seek nipple-sparing mastectomy. This difference, and its implications, should be considered carefully and discussed with patients who have ptotic breasts and/or large breasts before mastectomy, as it moves a greater number of patients into the group who may benefit from flap-based breast reconstruction if nipple-sparing mastectomy is also desired. It is not possible to completely reposition a spared nipple-areola complex without limitation using a full-thickness periareolar incision after implant-based breast reconstruction because there is no underlying blood supply of significance to independently perfuse the nipple-areola complex. Small et al. described two cases of mastectomy flap–based pedicled nipple transpositions to correct nipple malposition in implant reconstruction cases.[16] This technique leaves a long horizontal scar across the anteriormost face of the breast and allows for limited movement of the malpositioned nipple-areola complex. In addition, with this technique, even minor wound complications such as partial nipple-areola complex necrosis or incisional dehiscence could pose an infection risk or produce implant exposure necessitating explantation and resultant failure of the immediate reconstruction.

The large, ptotic breast is worth special commentary, as those patients have historically been discouraged from undergoing nipple-sparing mastectomy.[17] Preservation of the nipple-areola complex is more challenging because of difficulty managing retraction of the skin envelope during mastectomy and concern for ischemic complications. These issues do not, however, mean that women with large ptotic breasts are not candidates for nipple-sparing mastectomy as previously suggested.[7,17] In our series, we have shown a 100 percent success rate in terms of nipple-areola complex survival for women with grade II and III ptosis and mastectomy weights as high as 877 g (Fig. 4). The distance from the source blood supply in the periphery of the breast pocket to the preserved nipple-areola complex is certainly longer in a larger breast but, if the planes are managed carefully and the thermal plume in the

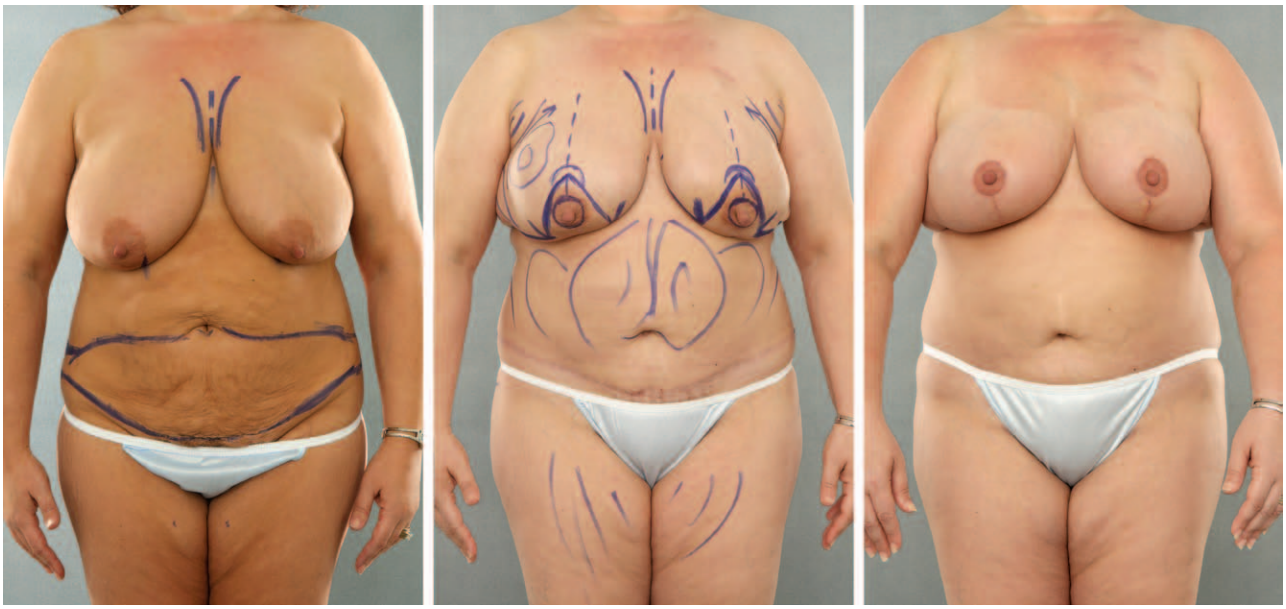

Fig. 4. Large-breasted patient with right breast cancer and grade III ptosis before bilateral nipple-sparing mastectomy and DIEP flap reconstruction (*left*). Presurgical markings before subsequent revision (*center*). After mastopexy with improved breast shape and nipple position (*right*).

electrocautery is held in check with intermittent energy bursts and sweeping technique,[18] the odds of a viable nipple-sparing mastectomy in the large-breasted patient undergoing nipple-sparing mastectomy are high. The worst-case scenario with an attempt at nipple preservation in these patients is a necrotic nipple-areolar complex in the early postoperative period that is simply excised with revision closure of the remaining surrounding skin. Although undesirable as a basic tenet, the consequences of a small area of necrotic skin in a flap reconstruction are less severe compared with an implant-based breast reconstruction because there is no risk of implant exposure and/or infection leading to implant loss. It has been previously demonstrated that the most common complications leading to implant loss are indeed infections and/or breast skin necrosis producing contamination or overt exposure of the prosthesis. Autogenous tissue–based reconstructions do not suffer the same potential for problems of this type, because the filler for the breast pocket is composed of independently vascularized material that tends to weather breast skin healing problems more reliably than do implant-based reconstructions.[19,20] This gives the operator, reconstructing the breast with a flap, more confidence when preserving the nipple in the large-breasted patient.

The breast skin healing complications that we identified were experienced following mastectomy, and there were no postmastopexy complications identified. All of these patients were treated with either simple débridement and revision closure of the remaining skin (seven breasts), or basic wound care and healing by secondary intention (six breasts). There were no cases of nipple-areola complex necrosis following the secondary mastopexy.

Based on these findings, the exclusion of those with breast ptosis, even when severe, is arguably irrational when the patient is otherwise a suitable candidate for nipple-sparing mastectomy. This is not true for those considering implant-based breast reconstruction because the reestablishment of an underlying, independent, blood supply for the preserved nipple-areola complex does not occur. For women with breast ptosis, the appeal of implant reconstruction may be lost if the breast cannot be lifted secondarily without loss of the preserved nipple-areola complex. Simply placing a larger implant to overfill the pocket is not always a sound solution and not always desirable for a variety of reasons, including potentially higher complication rates.[21] The liberty to completely translocate the nipple-areola complex at the second stage is a clear advantage that flap-based reconstructions enjoy over implant-based reconstructions.

CONCLUSIONS

The potential of an underlying perforator flap to revascularize the nipple-areola complex allows the reconstructed breast to be lifted with complete, full-thickness circumareolar incisions and peripheral undermining around the nipple-areola complex. This facilitates full repositioning of the nipple-areola complex relative to the surrounding skin envelope. Patients resultantly benefit from an improvement in nipple position, breast shape, and degree of ptosis. This represents a significant potential advantage of flap-based breast reconstruction over implant-based reconstruction in women with breast ptosis who desire nipple-sparing mastectomy. Developing proficiency in this technique adds a very powerful tool to the plastic surgeon's repertoire when counseling a patient with ptotic breasts and a desire for nipple-sparing mastectomy.

Frank J. DellaCroce, M.D.
1717 St. Charles Avenue
New Orleans, La. 70130
info@breastcenter.com

REFERENCES

1. Moyer HR, Ghazi B, Daniel JR, Gasgarth R, Carlson GW. Nipple-sparing mastectomy: Technical aspects and aesthetic outcomes. *Ann Plast Surg.* 2012;68:446–450.
2. Spear S. Nipple sparing mastectomy and reconstruction: Indications, techniques, and outcomes. In: Spear S, ed. *Surgery of the Breast: Principles and Art.* Vol. 1. 3rd ed. Philadelphia: Wolters Kluwer/Lippincott Williams & Wilkins; 2011:287–297.
3. Stolier AJ, Levine EA. Reducing the risk of nipple necrosis: Technical observations in 340 nipple-sparing mastectomies. *Breast J.* 2013;19:173–179.
4. Spear SL, Willey SC, Feldman ED, et al. Nipple-sparing mastectomy for prophylactic and therapeutic indications. *Plast Reconstr Surg.* 2011;128:1005–1014.
5. Hartmann LC, Schaid DJ, Woods JE, et al. Efficacy of bilateral prophylactic mastectomy in women with a family history of breast cancer. *N Engl J Med.* 1999;340:77–84.
6. Maxwell P, Whitworth P, Gabriel A. Nipple sparing mastectomy. In: Spear SL, ed. *Surgery of the Breast: Principles and Art.* 3rd ed. Philadelphia: Wolters Kluwer/Lippincott Williams & Wilkins; 2011:298–307.
7. Spear SL, Hannan CM, Willey SC, Cocilovo C. Nipple-sparing mastectomy. *Plast Reconstr Surg.* 2009;123:1665–1673.
8. Spear SL, Carter ME, Schwartz K. Prophylactic mastectomy: Indications, options, and reconstructive alternatives. *Plast Reconstr Surg.* 2005;115:891–909.
9. Spear SL, Rottman SJ, Seiboth LA, Hannan CM. Breast reconstruction using a staged nipple sparing mastectomy

following mastopexy or reduction. *Plast Reconstr Surg*. 2012;129:572–581.
10. Al-Mufarrej FM, Woods JE, Jacobson SR. Simultaneous mastopexy in patients undergoing prophylactic nipple-sparing mastectomies and immediate reconstruction. *J Plast Reconstr Aesthet Surg*. 2013;66:747–755.
11. Rivolin A, Kubatzki F, Marocco F, et al. Nipple-areola complex sparing mastectomy with periareolar pexy for breast cancer patients with moderately ptotic breasts. *J Plast Reconstr Aesthet Surg*. 2012;65:296–303.
12. Regnault P. Breast ptosis: Definition and treatment. *Clin Plast Surg*. 1976;3:193–203.
13. DellaCroce FJ, Sullivan SK, Trahan C, Jenkins CE. Body lift perforator flap breast reconstruction: A review of 100 flaps in 25 cases. *Plast Reconstr Surg*. 2012;129:551–561.
14. DellaCroce FJ, Sullivan SK, Trahan C. Stacked deep inferior epigastric perforator flap breast reconstruction: A review of 110 flaps in 55 cases over 3 years. *Plast Reconstr Surg*. 2011;127:1093–1099.
15. Place M. Basic techniques and principles in plastic surgery. In: Ashton SJ , ed. *Grabb and Smith's Plastic Surgery*. 5th ed. Philadelphia: Lippincott Williams & Wilkins; 1997: 13–26.
16. Small K, Kelly KM, Swistel A, Dent BL, Taylor EM, Talmor M. Surgical treatment of nipple malposition in nipple-sparing mastectomy device-based reconstruction. *Plast Reconstr Surg*. 2014;133:1053–1062.
17. Salgarello M, Visconti G, Barone-Adesi L. Nipple-sparing mastectomy with immediate implant reconstruction: Cosmetic outcomes and technical refinements. *Plast Reconstr Surg*. 2010;126:1460–1471.
18. Absten GT. *Practical Electrosurgery for Clinicians*. Marathon Shores, Fla: Professional Medical Education Association, Inc.; 2002.
19. Woerdeman LA, Hage JJ, Hofland MM, Rutgers EJ. A prospective assessment of surgical risk factors in 400 cases of skin-sparing mastectomy and immediate breast reconstruction with implants to establish selection criteria. *Plast Reconstr Surg*. 2007;119:455–463.
20. Patel KM, Hill LM, Gatti ME, Nahabedian MY. Management of massive mastectomy flap necrosis following autologous breast reconstruction. *Ann Plast Surg*. 2012;69:139–144.
21. Gdalevitch P, Ho A, Genoway K, et al. Direct-to-implant single-stage immediate breast reconstruction with acellular dermal matrix: Predictors of failure. *Plast Reconstr Surg*. 2014;133:738e–747e.